

Chapter 2 – The basic oral surgery techniques required for AQB implants

Instructor of Oral-Maxillofacial Surgery, Dentistry and Orthodontics,
The University of Tokyo Hospital
Hideto Saijyo

I. Securing Safety

A comprehensive view of patient's conditions must be gained due to the invasive nature of the implant surgery. The examination at the primary medical consultation is essential, and should be conducted according to the needs of the individual.

The suitability of the implant surgery must be analyzed prior to conducting the procedures and construct a treatment plan by implementing the information provided by the patient. The information can be derived from various sources, as stated in the section below.

A. Audit of patient's systemic conditions

Medical history, history of present disease, and in particular the presence of any concomitant diseases and its severity should be audited carefully, as this can affect the suitability of the implant treatment, or the treatment prognosis. It should also be made aware that smoking is an additional factor considered to influence the treatment prognosis.

B. Intraoral examination

- ① The extent of mouth opening: the treatment to the molar region can be difficult if the mouth opening is small.
- ② Conditions of the mucosa: the conditions of the mobile mucosa and attached mucosa should be closely inspected for the presence of any mucosal diseases.
- ③ Conditions of remaining teeth: ensure these are stabilized before the start of surgery to establish as much occlusal support as possible with the remaining teeth.

C. Model analysis

- ① State of the alveolar ridge: the shape of the alveolar crest should be noted. The presence of sharp ridge denotes treatment difficulties.
- ② Width of alveolar ridge: more than 1 mm of bone width is needed on both buccal and lingual sides with the placement of the implant body. It should be noted that the width of the alveolar ridge on the model should not be directly referred to as the actual bone width, as the actual width of the bone is thinner than it appears in some cases due to the thickness of the mucosa. This is typical in the maxillary anterior region therefore careful examination should be conducted for the determination of the actual width of the bone.
- ③ Excavation in apical base: a large excavation can lead to exposure of the implant body on the buccal side depending on the direction of insert.
- ④ Occlusal relationship: check clearance conditions. Treat the opposing tooth before the surgery if necessary, to secure clearance.
- ⑤ Occlusal condition: plan the occlusion with the placement of final superstructure against the

opposing teeth.

D. Image analysis

The location and shape of the floor of maxillary sinus, location of the nasal cavity and of the maxillary tuberosity have to be completely acknowledged for treating the maxilla. Meanwhile for the mandibular region, the positioning of the mandibular canal and the mental foramen need to be determined. These kinds of information are typically gathered with the following techniques:

- ① Panoramic radiographic examination: this is the most common means of examination although complementary examination techniques may also be necessary as the anterior region is difficult to be diagnosed due to the overlap with the cervical vertebrae.
- ② Dental photography: used to examine the state of the bone for the implant. It is possible to plan the size of the implant body to insert, by means of isometric photographing.
- ③ Examination by CT scan imaging: effective technique to determine the state of the maxillary sinus interior as well as the mandibular canal. The preoperative simulation has become possible in the recent years with the development of simulation software that can interpret the data from CT scans (DICOM: Digital imaging and communication in medicine) (Fig.3-2-1).
- ④ Three-dimensional model: insurance cover has been implemented since April 2008 simplifying its application. The model is created with the DICOM data obtained from CT scan. The reproducibility of teeth with this technique is still inferior to that of the study model; however, the jaw bone can accurately be remodeled. Some facilities have started to apply this in the surgery simulation (Fig. 3-2-2).

The treatment planning should incorporate the results from these analyses. Where complications in the procedure can be foreseen, the opinions of the implant specialists or doctors who are involved with the implant treatment may also be necessary.

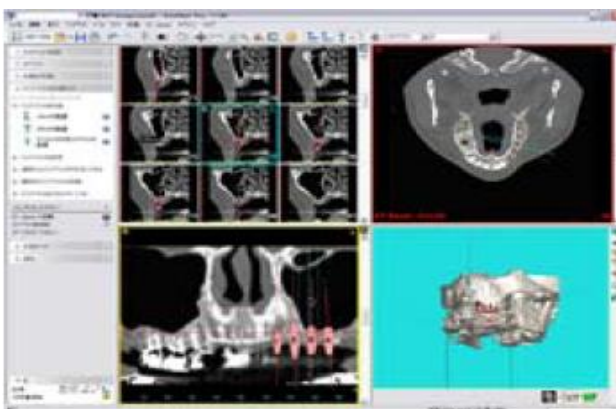


Fig.3-2-1
Preoperative simulation by simulation software (SimPlant Pro 11®)

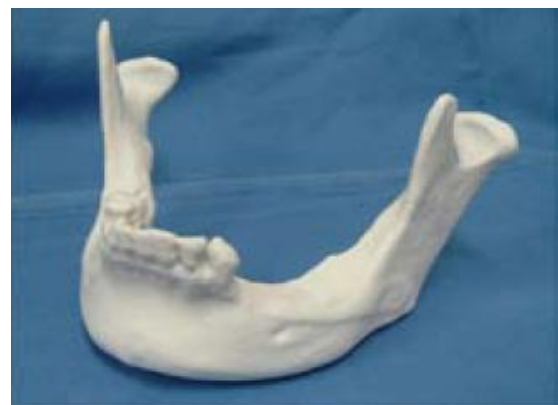

Fig.3-2-2
Three dimensional model. CAD data was formed from the DICOM data, then with the inkjet printer (Z403 3D printer® DICO) the additive manufacturing was conducted.

II. Anesthesia

Infiltration anesthesia is sufficient for the implant installation. However, for the patients who are suffering from high anxiety levels or are undergoing a course of multiple installation (Table 3-2-1, Fig. 3-2-3) intravenous sedation may be required. For the procedures affecting a wider area such as bone augmentation or where the bone needs to be extracted from an extraoral origin, general anesthesia may be necessary.

A. Local anesthesia

The local anesthesia can be divided into topical anesthesia, infiltration anesthesia and conduction anesthesia. The application of submucosal anesthesia and subperiosteal anesthesia (Fig.3-2-4) are common in dental surgery settings. Most of the implantation can be controlled with the subperiosteal infiltration anesthesia. Very rarely, the conduction anesthesia is applied to facilitate the multiple implantations to the mandibular molars, and the complications have to be noted. From my experience, concomitant induction of conduction anesthesia have not been necessary in the ordinary implant installations, even to the mandibular molar regions, provided that infiltration anesthesia has been sufficiently applied.

1. Ileus
2. Pneumothorax
3. Otitis media
4. Early stage of pregnancy (Within 3 months)
5. Patients who had a ophthalmic operation (Ocular hypertension)
6. Patients who are not able to nasal respiration
7. Mentally disabled patients
8. Bronchial asthma, hyperventilation syndrome and hysteria

Table 3-2-1

Contraindications to inhalation sedation with nitrous oxide

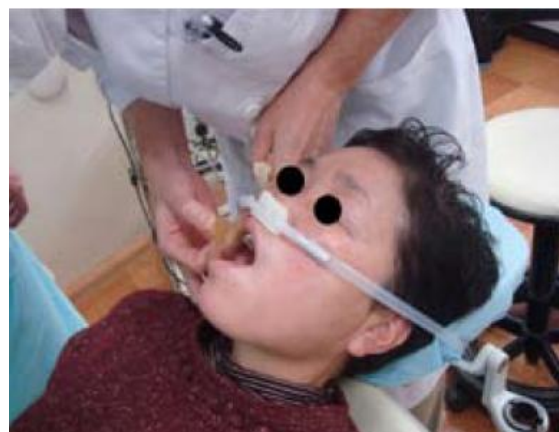

Fig.3-2-3

Nitrous oxide inhalation sedation technique

B. Practicalities of anesthetic method

Subperiosteal anesthetic method shall be discussed here as an example of anesthetics applied for implant installation.

Subperiosteal anesthesia is a method to inject the anesthetic agent by placing the injection needle into the subperiosteal position adjacent to the plane of the bone. The placement of the needle straight into the periosteal position can cause extreme pain on the individual, therefore the following method is recommended. If necessary, dry the mucosal plane before the application of the topical anesthesia, then inject the needle into the submucosal position surrounding the area of implantation. The anesthetic agent should be applied gently to avoid swelling of the mucosal tissues (Fig. 3-2-5). After a while, inject the needle further in and adjust its direction so that the cut surface is positioned in parallel with the plane of the bone for the application of the anesthetic agent. The liquid should be injected gradually as the sense of pain and of pressure is at its most with this procedure. Another note of caution is that the tip of the needle can become bent if it hits the plane of the bone with extreme force, and can subsequently lead to causing unnecessary damages to the periodontal tissues. The accuracy with which to apply the infiltration anesthesia to the subperiosteum not only improves the efficacy of anesthesia, but also the subsequent detachment of the periosteum becoming easy through hydro-dissection. The patient should be monitored for few minutes after the induction of local anesthesia, before initiating the surgical procedures.

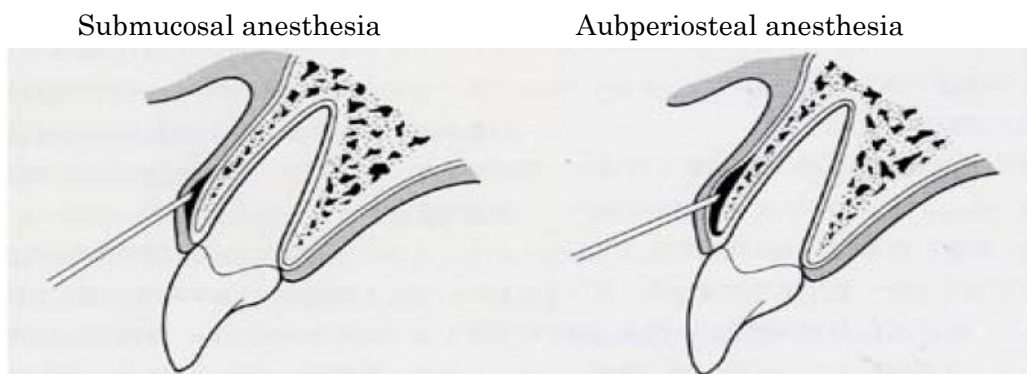


Fig.3-2-4 Submucosal anesthesia and subperiosteal anesthesia

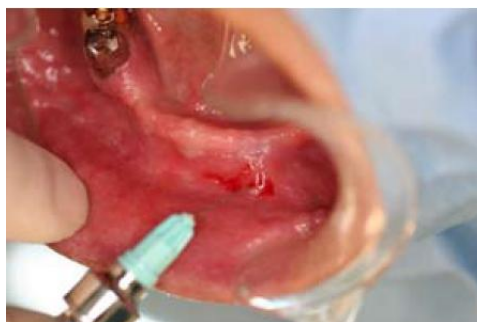

Fig.3-2-5 Infiltration anesthesia to alveolar mucosa

III. Incision

A. Design of the mucoperiosteal flap

The key to flap designs is to gain sufficient visual window, and to achieve blood supply. Essentially, the base of the flap should be formed larger than that of the tip (Fig. 3-2-6, 7). A release incision may be

applied to relieve the tension to prevent the unnecessary fissure at the time of suture (Fig. 3-2-8). This is of particular importance as the lack of mucosa is inevitable for conducting bone augmentation procedure therefore the flap design should be done with consideration to the state when the wound is closed.

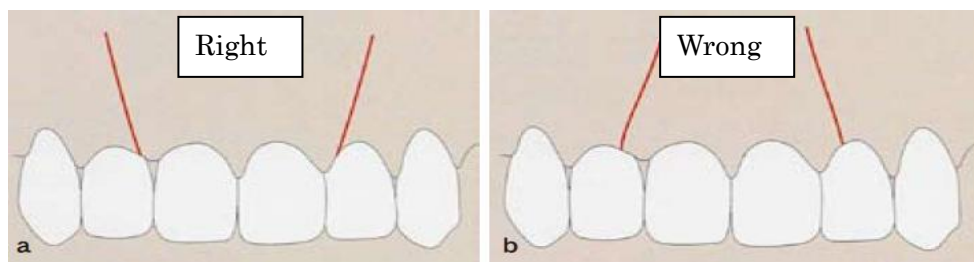


Fig.3-2-6-a,b
Mucoperiosteal flap design
Secure a sufficient area for the base of the flap, and obtain sufficient blood flow to the flap tip.

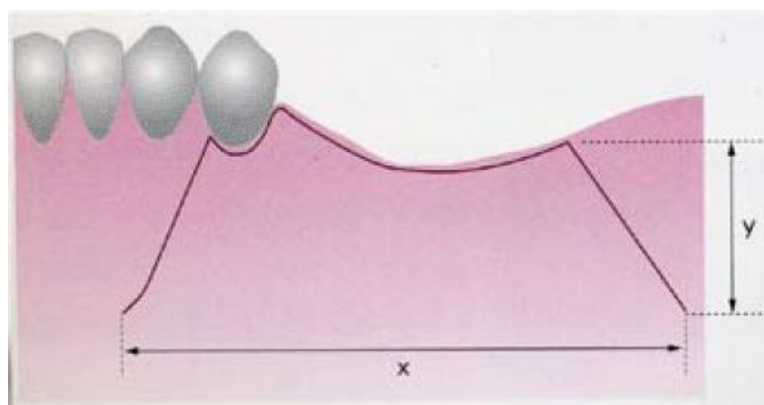


Fig.3-2-7
Incision line applied with consideration to the blood flow.
Sufficient blood flow can be obtained when $x > y$.
 $x = 2y$ has been said to be the ideal according to Happ, 1998.

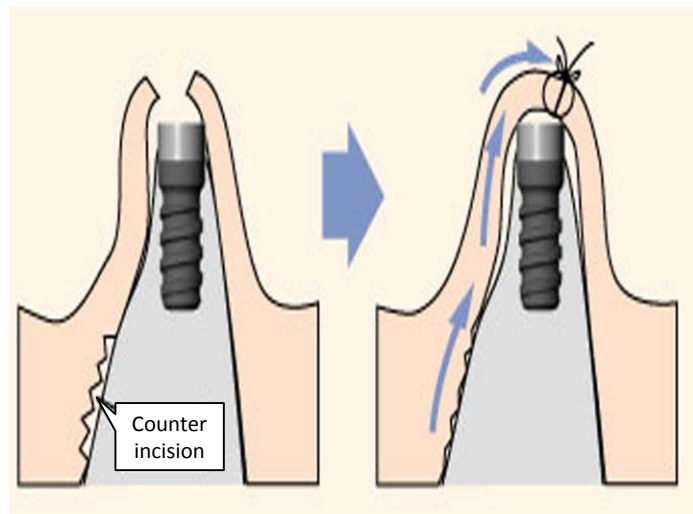


Fig. 3-2-8 The release incision scheme

B. Incision with scalpel

There are No. 15, 12 and 11 scalpels that are under current usage in the dental field (Fig. 3-2-9). Each of these scalpels has their characteristics therefore they must be employed having understood their properties. The No. 15 scalpel has been deemed the most suitable for mucoperiosteal flap formation.

C. Points of caution for incision

The use of surgical skin marker (Fig. 3-2-10-a) on the mucosa may be effective in determining the positions (Fig. 3-2-10-b). When forming the incision, pen-holding grip is an effective way to hold the scalpel (Fig.3-2-11). The incision should be primarily applied to the alveolar ridge when the sharpness of

the scalpel is at its upmost. There have been sightings of incision with weak forces to be applied repeatedly but as this can cause a number of minute cuts in the wound and delay the healing process. They should be applied in continuous long strokes instead. It is surprisingly challenging to incise into the periodontal ligament of the adjacent tooth, in which case a concomitant application of No. 12 scalpel or a pair of scissors may be useful.

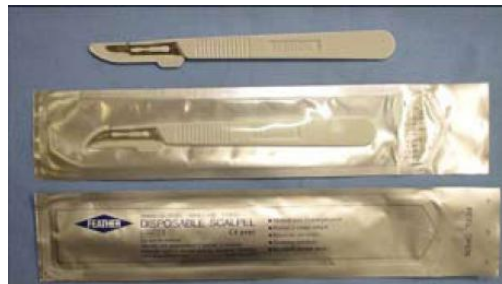

Fig.3-2-9
Types of scalpels that are used in dental clinical settings.

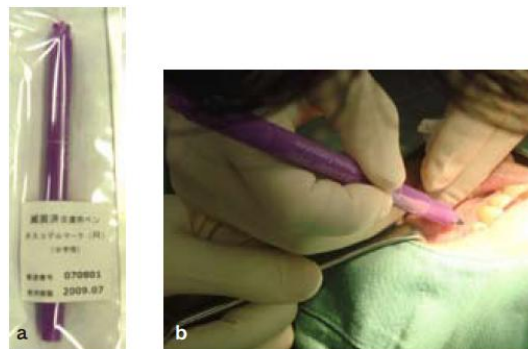


Fig.3-2-10-a,b
Surgical skin marker (a) and designing the incision line (b)

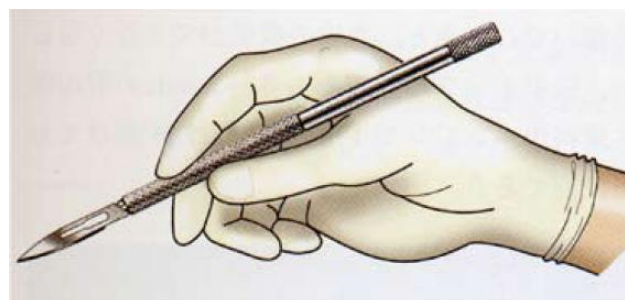


Fig.3-2-11
Holding manner of a scalpel ²⁾
Pencil grip is the ideal holding manner for incision in the oral cavity.

D. Countertraction method

Countertraction is a simple surgical technique that is also applicable for the intraoral surgery. This is applied to facilitate the incision step following by application of incision to the periosteum while stabilizing the mucosa with tools such as tweezers.

IV. Detachment

The detachment and elevation of the mucoperiosteal flap should be conducted carefully to avoid crushing the structure that will eventually cover the bone surface in the surroundings of the implants.

There are two types to raspatories: periosteal elevator and mucosal elevator. Each of these has been developed to have specific purposes (Fig. 3-2-12).

There are two heads on the two extreme ends, one with a small pointed head and a larger head on the opposing side, and an ideal mucoperiosteal flap can be constructed by differentiating their use. More precisely, at the initial stages of periosteal detachment, use the smaller sharp end, and while holding the mucoperiosteal flap with the tweezers to lift it with tension. The larger surface of the raspatory becomes necessary once the elevation has been initiated. To prevent any damages done to the elevated mucoperiosteal flap, the surface of the raspatory should always face the bone (Fig. 3-2-13). The flap elevation should be limited to the minimum to avoid postoperative complications such as swelling as much as possible.

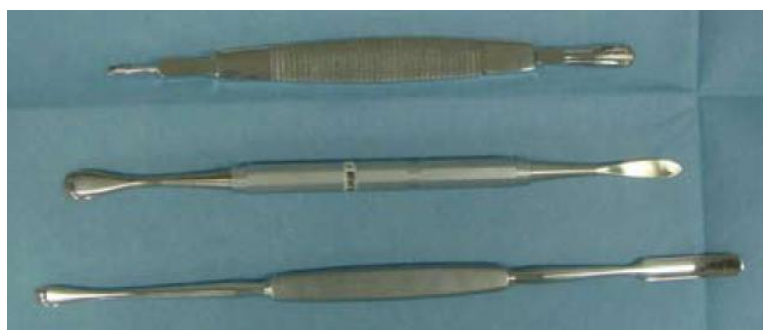

Fig.3-2-12
Periosteal elevator (Top, middle) and
mucosal elevator (Bottom)

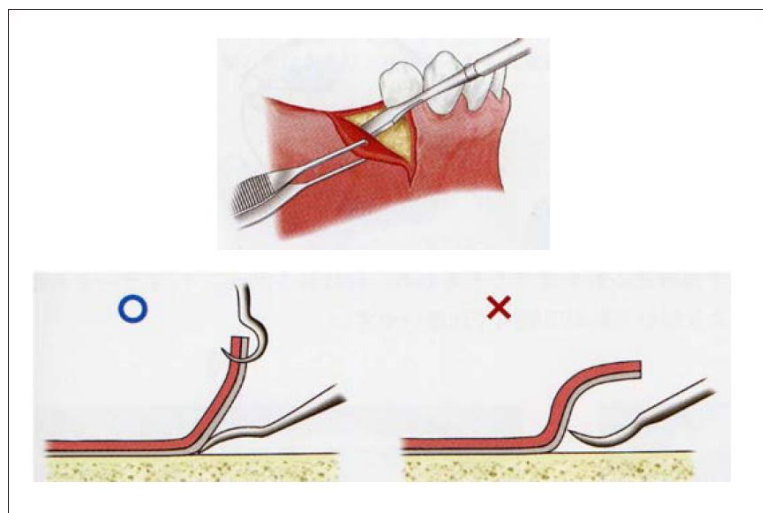


Fig.3-2-13 How to use a raspatory ²⁾

V. Confirmation and determination of the implant positioning

The underlined rule with implant treatment is to replace the lost tooth with one implant, but since the size of the implant and the innate tooth do not always correspond to each other, the number of implants and the actual teeth are not equal. The implant body is to be installed with distance of 3 mm away from the adjacent natural tooth. The reasons for this are to avoid the base of the implant body from interfering with the tooth roots, and to achieve a natural appearance.

The determination of the installation position before the surgery with the use of study model and imaging

analysis is needless to say, but there are cases where the image is difficult to be obtained with the exposed state of the bone. For the installation of one or two implant bodies, the importance of simulation is may not be obvious, but with multiple implantation, the errors are more apparent and can become more significant. The effective method in such cases would be to mark on the bone surface with a sterilized pencil or crystal violet (pyoctanine, which requires a dry surface).

VI. Suture

A. Choice of apparatus used in suture

1. The different types of suture thread and its selection

The suture threads are classified accordingly to the material it is made from and its structural form: natural or synthetic origin, subdivided into absorbable and non-absorbable types, and finally into single filament or braided multiple filament types (Fig. 3-2-14).

Typical example of a natural thread is the braided non-absorbable silk type, it is pliable, easy to handle, simple to tie a knot with, and is highly hydrophobic.

There are absorbable and non-absorbable types to synthetic suture thread, and nylon thread is an example of the absorbable type, which are available in both monofilament and braided forms. Each have their distinguishable properties. Monofilament causes the least damages to the tissues at the time of suturing, least likely to attract microorganisms, and is easy for the knot to slip down. However, due to its vulnerability to mechanical damages, when holding the thread with the forceps or tying surgeon's knot one should be careful not to apply excessive torsion.

On the contrary, the braided nylon thread is more difficult to thread through and is at higher risk of damaging the tissues and accumulation of microbes within the braids; though it has its advantages in handling due to its pliable nature; and its ease in tying a knot that does not bulk out.

The suture sizes are represented by their diameters. Under the UPS standards that is generally used, the threads of 10...3, 2, 1, 0 (1-0), 2-0, 3-0...12-0 are available. The diameters of 3-0 to 5-0 are commonly used, and personally, 4-0 is often employed for implant surgery.



Monofilament



Braided

Fig.3-2-14 Monofilament and braided suture threads

2. The different types of suture needle and its selection

Suturing needles consists of three different sections, the swage (junction of a needle and a suture thread), the body and the tip (point of the needle). The length of the needle indicates the total length of the needle (the distance of the arc from the point to the swage) (Fig.3-2-15).

a. Types of needle

The types are differentiated according to their shape of swage, the degree of curvatures and shape of the tip.

1) Classification according to shapes of the swage (Fig.3-2-16)

Classified according to the forms of the junction of a needle and the suture thread, the different types are: spring eye needle, a regular eye needle, and an atraumatic needle (yarn needle). The magnitude of damage caused with these passed through the tissues are in the order:

spring eye needle > regular eye needle > atraumatic needle.

2) Classification according to the curve (Fig.3-2-17)

There are curved needles, weakly curved needles and straight needles distinguished with the extent of the curvature, and are referred to as 1/2 circle curved, 3/8 circle curved, 5/8 circle curved and 1/4 circle curved in accordance to the length of needles and to their curvature. Uses of 1/2 circle curved needles and 3/8 circle curved needles are common in minor oral surgery.

3) Classification according to shapes of tip

Suture needles are divided into tapered needles, reverse cutting needles and cutting needles according to their different tip forms. The tapered needles are mainly applied to the tissue structures that are soft and are easy to pass through, and are the most commonly used suture needle. The reverse cutting needle is generally called a “cutting needle”, with a third blade on the exterior, with the internal structure to be the base of the triangle. It is typically used on the hard tissues like the epithelium. The cutting needle can only be applied for specific purposes such as the preparative steps, due to the presence of a tertiary blade that faces inwards that can rip the tissues during the suturing procedure.

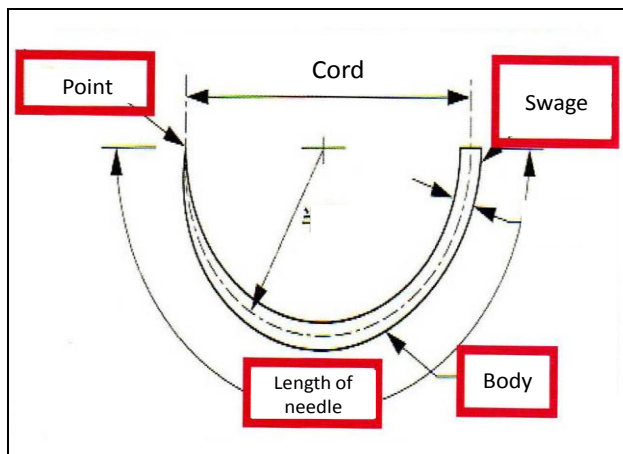


Fig.3-2-15 Structure of suture needle

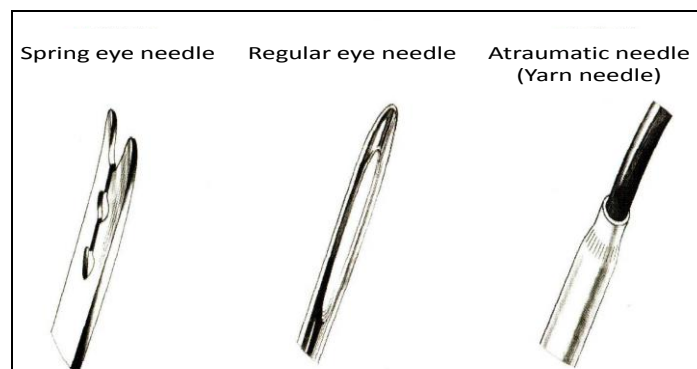


Fig.3-2-16 Classification according to shapes of the swage

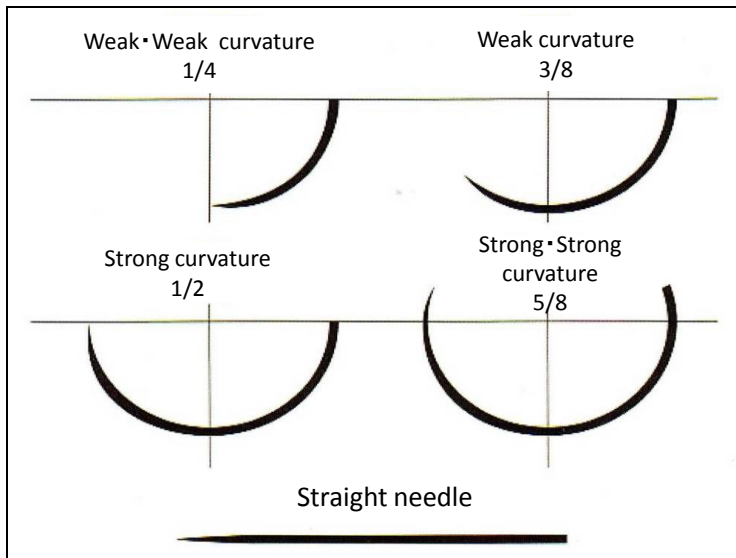


Fig.3-2-17 Classification of suture needles according to curvature

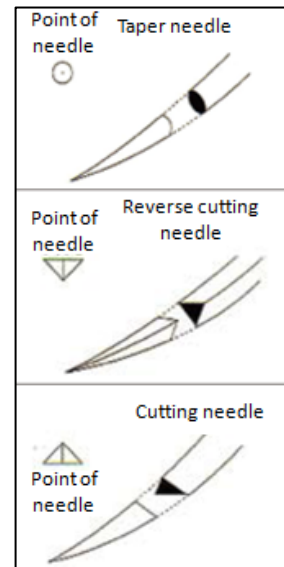


Fig.3-2-18 Classification of suture needles according to shapes of point

b. The basis of needle selection

The objective of the suture needle is to direct the suture thread in order to stitch the tissues together. Therefore other damages should be limited to the minimum. Generally, the use of tapered needle and cutting needle is differentiated by the softness of the tissues. The tapered needle for more soft tissues and the cutting needle for the harder that require more effort to pass the needle through it. Having said that, the tapered needle can be used even to saw the mucoperiosteal flap.

The length, thickness and curvature of the needles should be selected depending on the objective, and with regards to the thickness of the needle, this should be chosen to fit the thread selected.

B. Suture technique

1. The basic methods of suturing

a. Basics of suture

- The needle holder is to be held so that it is supported with the index finger, and draw a circle with it. The holding manner is illustrated in Fig. 3-2-19.
- The suture needle should be held firmly with the tip of the holder, 1/3 to 1/2 of the distance from the swage towards the tip of the needle (Fig. 3-2-20).
- The needle should always be inserted perpendicular to the plane of the tissues (Fig. 3-2-21).
- The needle should be passed through the tissues along the curvature of the needle (Fig. 3-2-22).
- Rotate the needle holder in the palm of the hand, and let it slide as to ladle the tissues with the curve.
- The needle should be drawn out through the tissues along its curvature also for its removal.
- The needle to be removed vertically from under the tissues of the opposing side.
- Avoid any shift in the position or the height of the connective tissue layers (Fig. 3-2-24).
- The suture thread should not be tied too tightly
- If tied too tightly, the blood flow can be obstructed leading to tissue necrosis.

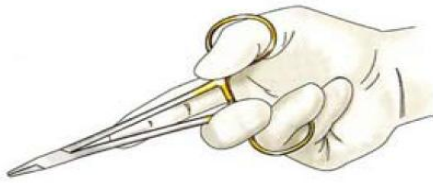

Fig.3-2-19 Holding the needle holder

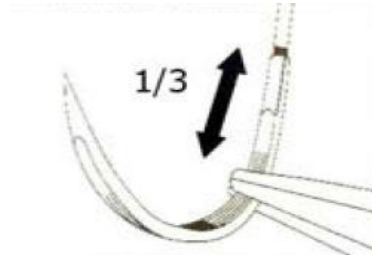


Fig.3-2-20 Holding position of needle

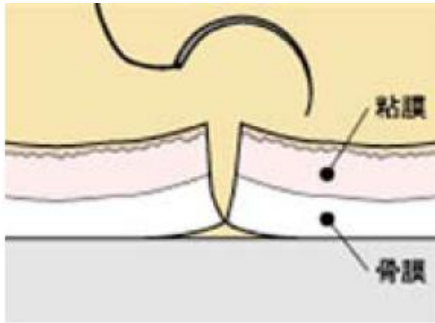


Fig.3-2-21

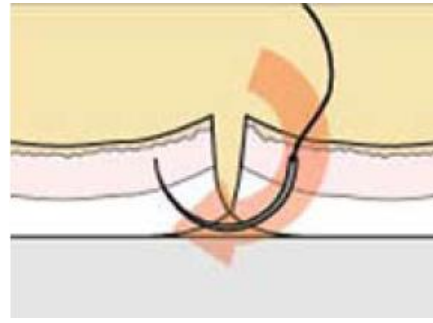


Fig.3-2-22

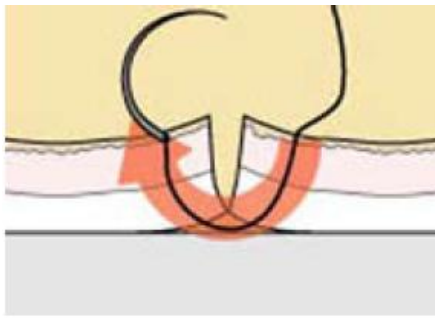


Fig.3-2-23

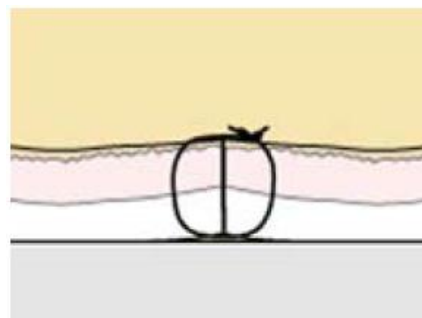


Fig.3-2-24

b. Simple interrupted suture (Fig. 3-2-25)

This is the most basic suture method. The knots should be formed on one side for convenience at the time of suture thread removal. The detailed suturing technique is illustrated in Fig. 3-2-26 a to e.

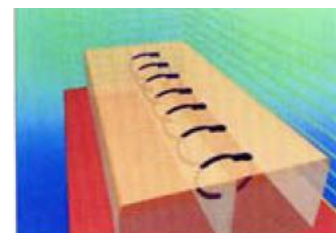


Fig.3-2-25 Simple interrupted suture

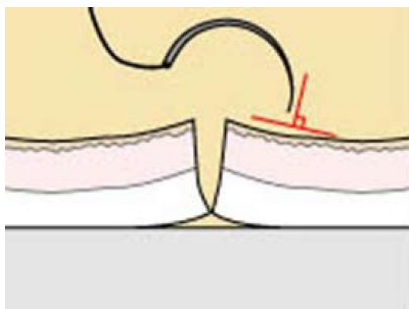


Fig.3-2-26-a Insert the needle into the skin at right angles

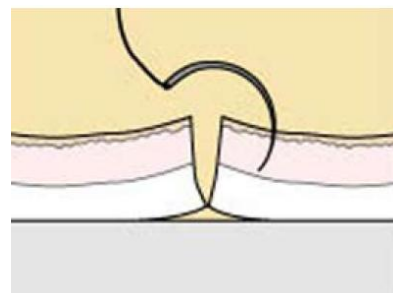


Fig.3-2-26-b Rotate the needle holder in the palm of the hand with the curvature of the needle.

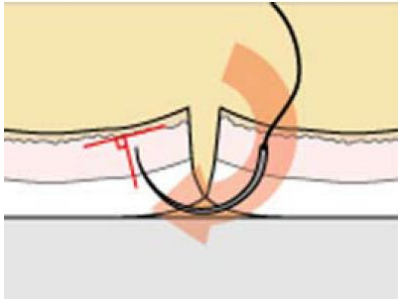


Fig.3-2-26-c
Draw the needle perpendicularly from under the opposing tissues

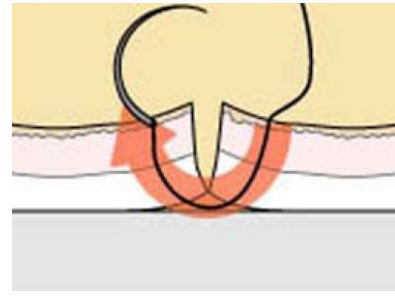


Fig.3-2-26-d
The same rotating movement should be applied when removing the needle.

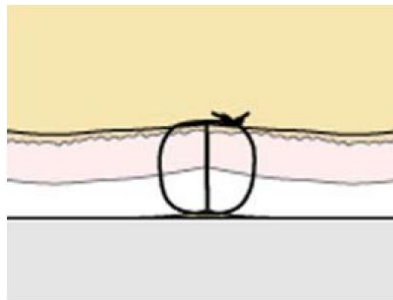


Fig.3-2-26-e
The complete picture - Place the knots on one side for it to be convenient at the time of thread removal.

c. Vertical mattress suture (Fig.3-2-27)

This is a suturing method whereby the suture is first applied to the deep layers of the wound, then reverse the needle to suture the wound through the superficial layers. In comparison with the interrupted suture, the vertical plane of the layers can meet more precisely. Too much tension in the thread can cause tissue necrosis or leave cicatrix therefore it is recommended to tie the knot loosely, and aim to remove the threading early. Simple interrupted suture is sufficient under the normal surgical settings, but where there is significant strain applied on the flap, the use of vertical mattress suture is recommended.

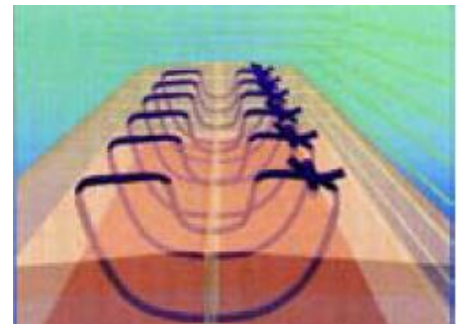


Fig.3-2-27 Vertical mattress suture

The details of vertical mattress suture are illustrated in Fig. 3-2-28 a to h.

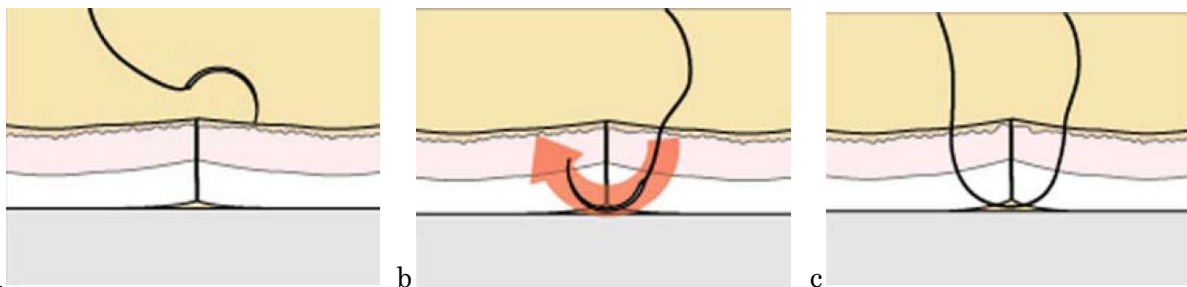


Fig.3-2-28-a ~ c

Conduct the suturing to the deep layers in the same manner as the interrupted suture.

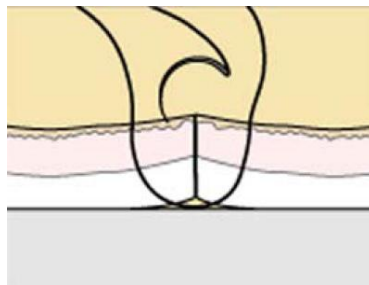


Fig.3-2-28-d Reverse the needle

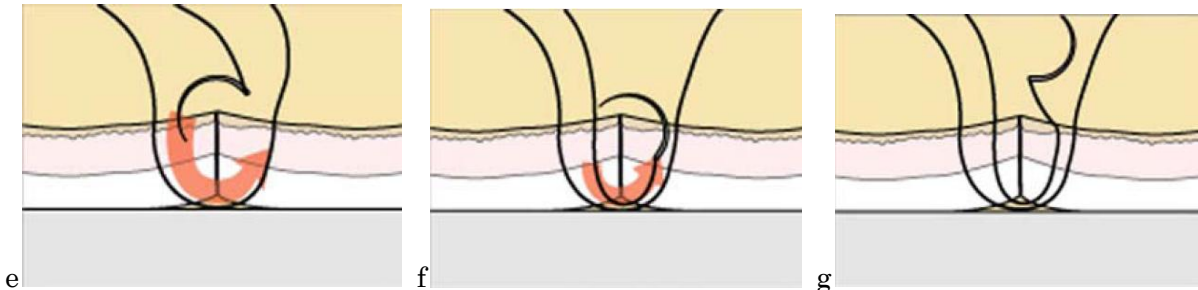


Fig.3-2-28-e ~ g

A reverse suture should be applied as close to the vertical edge of the wound as possible.

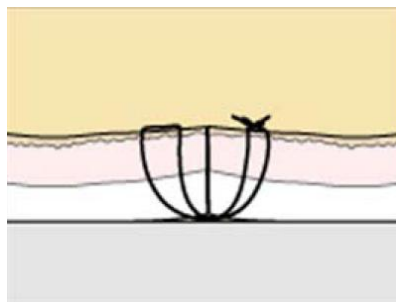


Fig.3-2-28-h The final picture.

Be careful not to knot too tightly.

2. Variations and manners of knot-tying

a. The general principles of knot-tying

The suturing should be conducted with an utmost care for wound closing. If the suture is done roughly or in a rush, a complete cover may not be able to be obtained. In the knot making, there are concerns as to the strain that could be applied to the tissue layers with the knot tying, as well as to the postoperative edema that could arise. The general principles that are applied to handling all suturing materials are as follows:

- The knot should be tied firm enough so that it does not become undone.
- The knot should be small and with only a few mm of the thread left remaining at the end to limit the tissue rejection or reaction to the foreign matters as much as possible.
- Avoid causing damages to the suture material in its handling.
- To prevent accidents such as tissue damage or snapping of the thread, avoid exerting too much tension on the string.
- To prevent circulation restriction to the tissues, avoid exerting excess tension on the thread for interaction of the tissues.
- Once the first knot is tied, do not let the thread slacken before tying the second knot.
- The surgeon should not hesitate to change his/her stance or position in relation to the patient for a

secure placement of the knot.

- An increase in the number of knots does not correspond to increase in strength.

b. Types of knot-tying

The common types are: square knot, granny knot, surgeon's knot, and multiple knots.

1) Square knot (Fig.3-2-29-a)

The second knot is tied in inversely to the original. This knot is unlikely to come undone, therefore is the most common technique.

2) Granny knot (Fig.3-2-29-b)

The first and the second knots are tied in the same direction. It is easy to apply but also easy to come undone. Not commonly applied.

3) Surgeon's knot (Fig.3-2-29-c)

The thread is wrapped around twice in the tying the first knot which helps to avoid the knot loosening before tying the second knot. It is least likely to come undone, but the disadvantage of this is the widening of the knot, creating a gap between the first and the second knot, which can consequently loosen the knot.

4) Multiple knots (Fig.3-2-29-d)

This is applied to situations where the double knot is inadequate and where there is a risk of the knots coming undone. The additional knots are generally applied inversely to the previous knot.




a Square knot



b Granny knot



c. Surgeon's knot



d. Multiple knot

Fig.3-2-29-a to d Types of knot-tying

c. Techniques of knot-tying

1) Two-hand technique

This is the most common tying method, using both hands to exchange the thread between them. A relatively wide space is required to allow for the movement of both arms.

2) One-hand technique

Only one hand is used to tie the knot. This is effective for situations where one side of the thread needs to be shortened; or where the knot-tying has to be conducted in a restricted amount of space.

3) Instrumental tie

The knot is tied with the use of needle holder, where the space is restricted or where the length of the thread is limited.

d. Practical of knot-tying

1) Square knot <Two-hand technique>

The details are illustrated in Fig. 3-2-20 a to l.

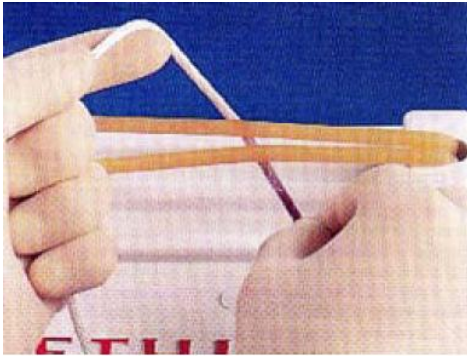

Fig. 3-2-30-a

White strand is to be placed over the extended index finger of the left hand, and held in the palm of the left hand. Purple strand is to be held in the right hand.

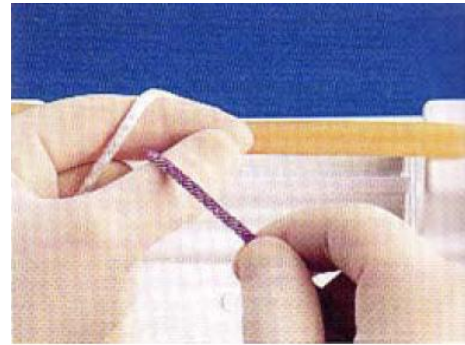


Fig. 3-2-30-b

Purple strand in the right hand is to be brought between the left thumb and the index finger.

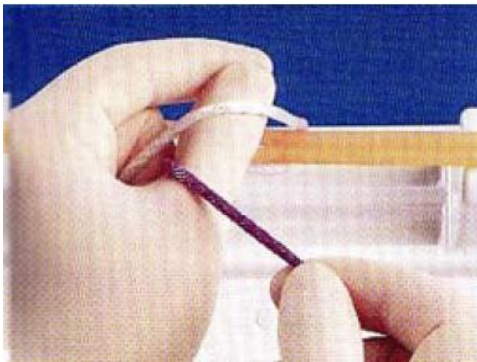


Fig. 3-2-30-c

Twist the left hand and turn so that the left thumb is placed under the white strand to form the first loop.

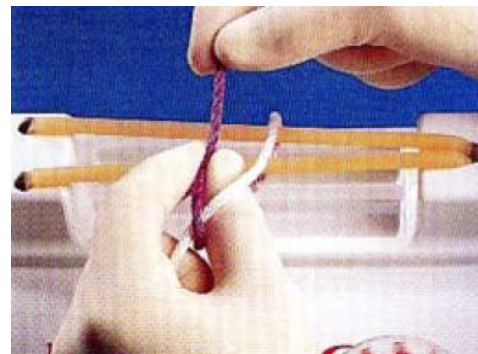

Fig. 3-2-30-d

Cross the purple strand over the white and hold these between the thumb and the index finger with the left.

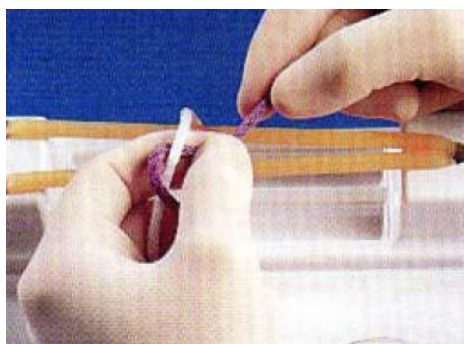

Fig. 3-2-30-e

Release the purple strand temporarily from the right hand. Then twist the left hand holding the purple strand in between the thumb and the index finger, to take the purple strand through the white loop. Gain hold of the purple strand with the right hand again.




Fig. 3-2-30-f

Release the purple strand from the left hand and hold it with just the right hand. Exert horizontal tension by placing the left hand towards the front of the surgeon him/herself, and the right hand away. The first knot is completed as thus.

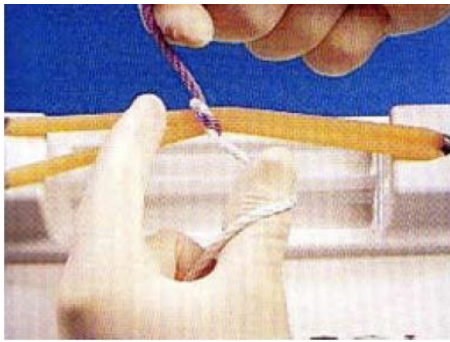


Fig. 3-2-30-g

Remove the left index finger from the white strand, wind it around the left thumb, and slide the purple strand held in the right hand to the left.

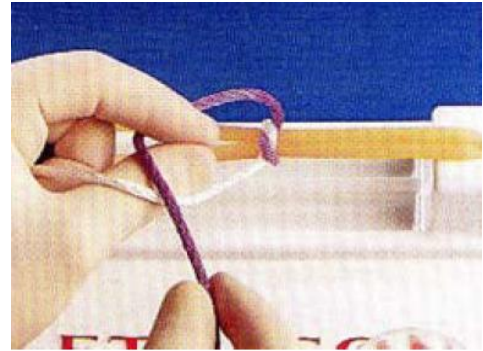


Fig. 3-2-30-h

Bring the purple strand held with the right hand towards the surgeon position it between the left thumb and the index finger, to cross with the white strand.

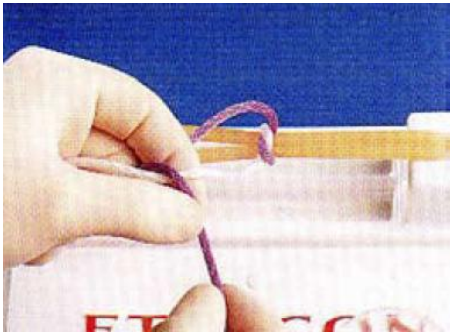


Fig. 3-2-30-i

Twist the left hand further towards the front, and place the index finger within the loop. Hold the purple strand between the left index finger and the thumb.

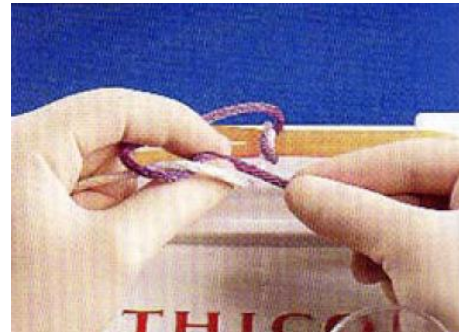


Fig. 3-2-30-j

Rotate the left hand away from the front, pass the purple strand held in between the thumb and the index finger through the loop, and then hold this with the right index finger and the thumb.

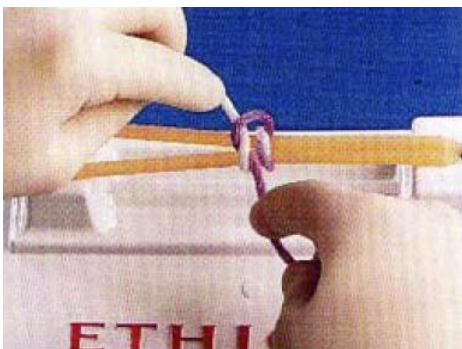


Fig. 3-2-30-k

Position the right hand towards the body of the surgeon, and the left hand away from the body of the surgeon and apply tension horizontally. The second knot is completes as thus.

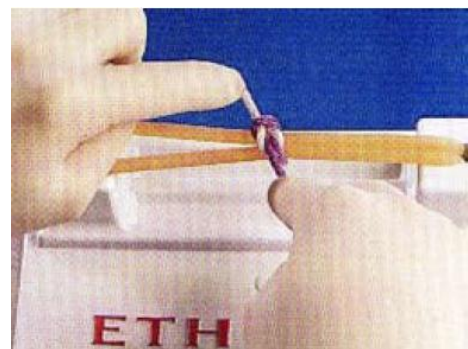


Fig. 3-2-30-l

The final tension should be applied as horizontally as possible.

2) Square knot <Two-hand technique>

Fig.3-2-30 a to l.

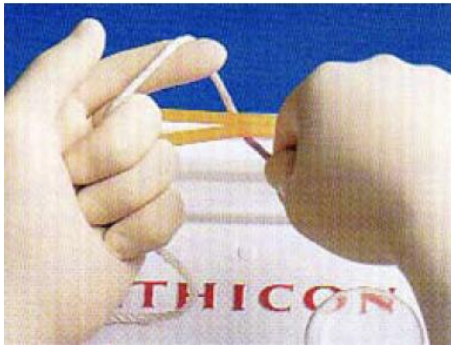

Fig. 3-2-31-a

White strand held between thumb and index finger of left hand with loop over extended index finger. Purple strand held between thumb and index finger of right hand.

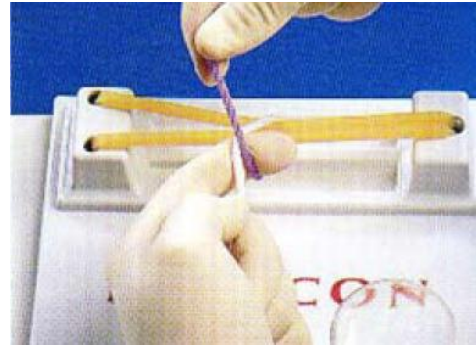


Fig. 3-2-31-b

Hook the extended white strand on the left index finger and hold the purple strand with the right index and thumb. Reposition the right hand away from the front section while hooking it on the left index finger to place it on top of the white

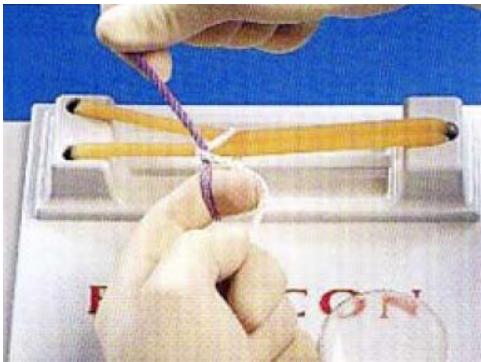


Fig. 3-2-31-c

While holding the purple strand, shift the white strand to the right to place this at the tip of the left index finger then pass it through the loop.

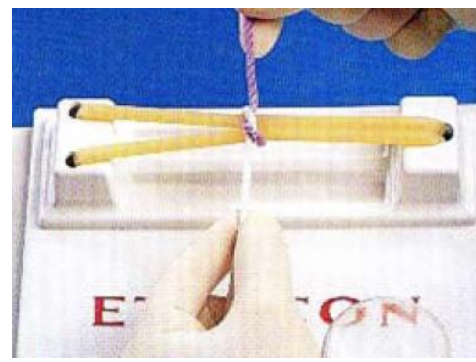


Fig. 3-2-31-d

Pull the white held with the left towards the front, and the purple away from the forefront section, and exert tension so that the knot is positioned horizontally. This completes the first knot. .

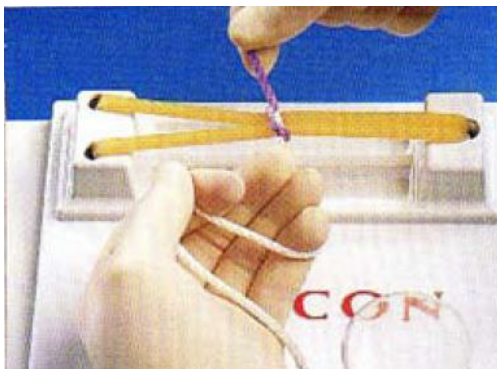


Fig. 3-2-31-e

Grip the white with the left index and thumb, turn the hand so that the palm becomes visible. Hold the other end (purple) with the right.

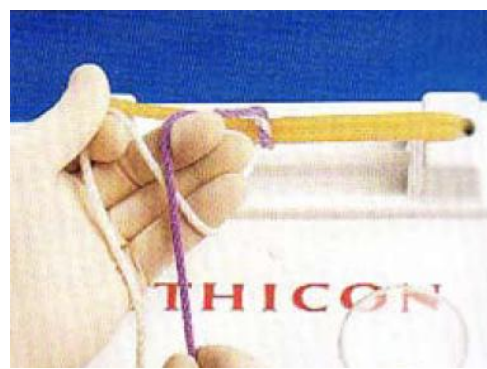


Fig. 3-2-31-f

Bring the purple strand towards the front then place it on the left middle finger to form a cross with the white strand.

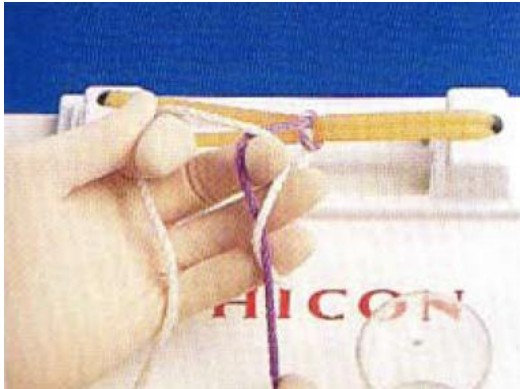

Fig. 3-2-31-g
Stabilize the purple strand held with the right hand by the left middle finger, hook the white strand also with the middle finger and then to pull it into the loop.

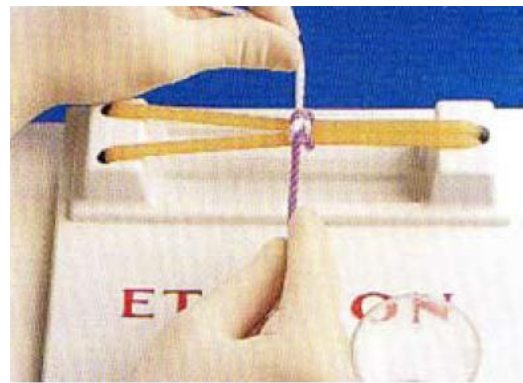


Fig. 3-2-31-h
Hold the white strand pulled through the loop with the left hand, and pull it away from the forefront section, and hold the other end (purple) with the left to be pulled towards the forefront. Complete the second knot with applying tension so that the knot is placed horizontally.

Surgeon's knot <Two-hand technique>

The details of this technique are illustrated in Fig.3-2-32-a to l.

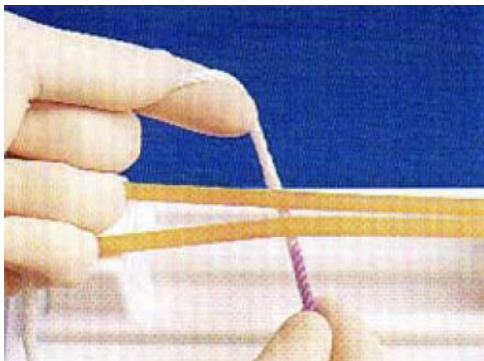


Fig. 3-2-32-a
Hook the white strand on the left index finger, and hold the rest with the palm of the hand. Hold the other end of the strand (purple) with the right index finger and the thumb.

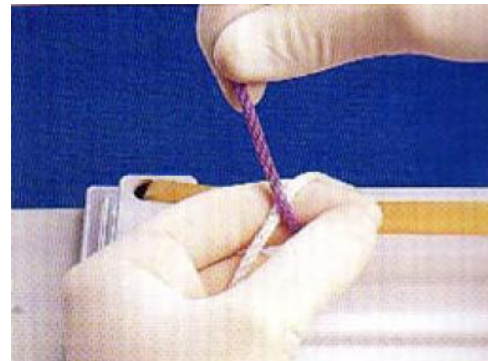


Fig. 3-2-32-b
Cross the purple strand held with the right from the forefront to the back, after wrapping it around the left index finger, on top of the white strand that is already positioned on the index finger. Place the tip of the index finger with the thumb.

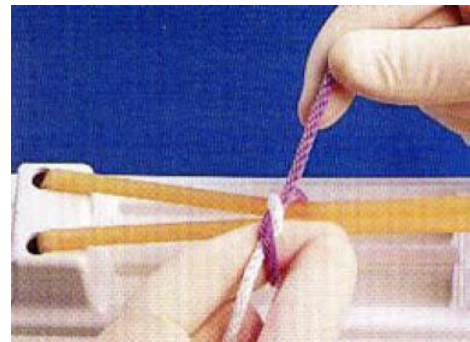
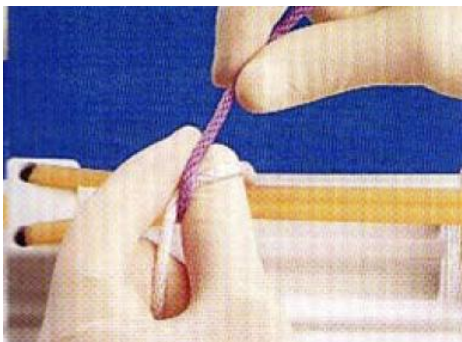
Fig. 3-2-32-c

Twist left hand so that the tips of the fingers are facing away from the forefront section, and shift the white strand so that it is on the thumb. Hold the purple strand in between the left index finger and the thumb, to free the right hand.

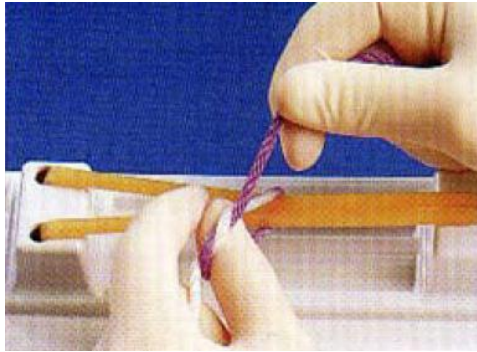


Fig. 3-2-32-d

Turn the left hand neck towards the forefront, pass the purple strand, held with the left, through the loop, and gain hold of the purple strand with the right hand.

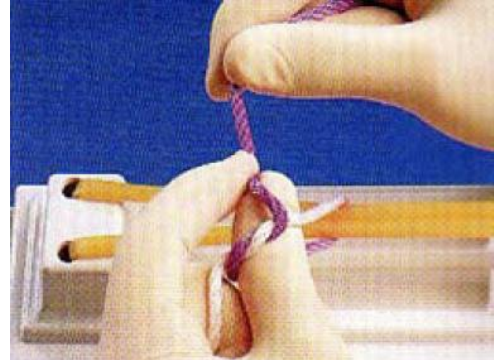

Fig. 3-2-32-e

Place the left thumb within the loop again.

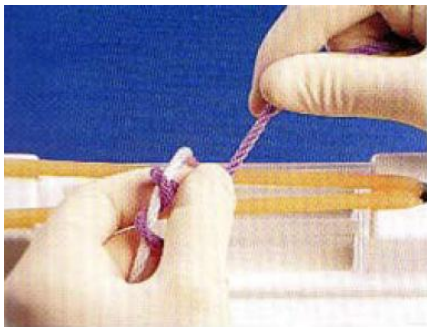


Fig.3-2-32-f

Shift the purple strand held with the right, to the left side, and grip with left index and the thumb

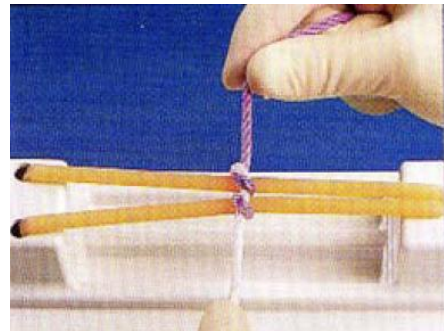


Fig. 3-2-32-g

Twist the left hand slightly towards the forefront section, and place the index finger in the loop, and pass the purple strand to be held with the right. This completes the second knot.




Fig. 3-2-32-h

Position the white strand held with the left, towards surgeon's body and the purple strand held with the right in the opposite direction, away from the front section to exert a tight horizontal pull. This knot cannot be tightened later.




Fig. 3-2-32-i

Wrap the white strand, held with the left, around the left thumb by twisting the thumb from below. Pass the purple strand through the left index and thumb on top of the white strand.

Fig. 3-2-32-j

Grip the purple strand with the left index finger and the thumb through the loop made with the white strand, to release the right hand.

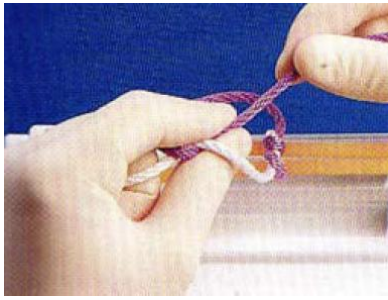


Fig. 3-2-32-k

Rotate the thumb of the left hand, holding the purple strand, away from the forefront section, and then regain hold of the purple strand with the right hand after passing it through the loop to complete the second throw square.

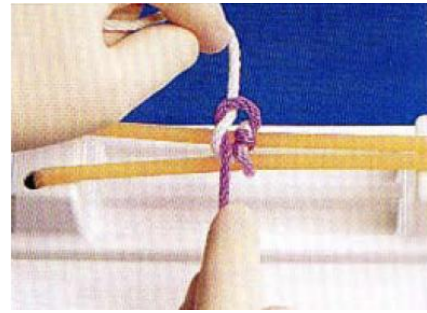


Fig. 3-2-32-l

Position the left hand, holding the white strand away from the body, and the right hand, with the purple strand, towards the body, to exert horizontal pull on the knot.

Hands continue to apply horizontal tension with left hand away from and right hand toward the surgeon. Final tension on the final throw should be as nearly horizontal as possible.

C. Points of suture in implant surgery

- ① Conduct so as to prevent any damages cause on the mucoperiosteal flap
- ② Insert the needle perpendicularly to the mucoperiosteal flap and ensure that the periosteum has been grasped firmly.
- ③ Aim to relieve any tension on the mucosa. Apply sufficient amount of release incision where there is tension.
- ④ Apply the suture so that the pressure exerted on the mucosa is sufficient to hold the mucoperiosteal flap together, and that it is applied equally on both flaps. In actual fact, the right amount of pressure for suture is when the mucosa turns slightly white.
- ⑤ Aim to leave few mm in between the thread.

References

- 1) Koga T. Implant surgery, Basic. Tokyo. Quintessence Publishing Co., Ltd. 2007; 2-5. (in Japanese)
- 2) Katsuki T, Uchida Y. Basis of surgery and surgical anatomy for implant/oral surgery. Tokyo. Quintessence Publishing Co., Ltd. 2007; 36-37. (in Japanese)
- 3) AQB Research Group. Basics and clinical practice of AQB implants (Vol.1 The Basics) 1st ed, Tokyo. ADVANCE Co., Ltd.2008; 82-91. (in Japanese)
- 4) Oral surgical procedure (Vol.1) 1st ed. Tokyo. Ishiyaku Pub, Inc. 2000; 31-38. (in Japanese)