

Chapter 3- Cases where bone augmentation technique was applied.

- With GBR

1. A case where the fixed prosthesis was set after implantation with GBR.

Chief Director of Niwa Dental Office

Ken Niwa

For an implant placement, bone quantity is an important factor. If a sufficient quantity of the bone cannot be obtained, GBR technique is applied. Generally, implantation procedure is conducted once bone regeneration has been completed, however in instances where the conditions are fit, GBR and implant insertion can be done concomitantly. In such instances, the primary stability is less stable and can be subjected to failure; therefore two-piece implant is often used. This increases the incidences of complications and microgap.

Applying the GBR technique concomitantly, we present a case whereby the problems of two-piece type were overcome by the use of AQB one-piece implant.

Patient: 60 year-old female

First admission: December 2006

Chief complaint: Inflammation of the gum, and pain while chewing.

Treatment plan: Implant one-piece type concomitantly with the application of GBR technique to achieve fixed prosthesis.

No. 18 and 19 teeth were judged to be unsustainable (Image-1) therefore were extracted (Image-2,-3). The height of the bone was examined by radiography. Due to the large size of the extracted cavity, the distance to the mandibular canal was short (Image-4) therefore was concluded that the bone quantity was inadequate to achieve primary stability.

Incision and detachment of the mucosal membrane at the point of implant were conducted under sufficient induction of local anesthesia. As predicted, the presence of a large cavity was confirmed (Image-5).

To 0.1 mm thickness titanium mesh, holes that would correspond to the implanting sites were formed first using a circular knife (Image-6). It was then trimmed to provide a more suitable fit around the implant site (Image-7,-8).

First a suitable sized implant was planted, and bone filling agent, that is a mixture of demineralized freeze-dried bone allograft (DFDBA) and hydroxyapatite (HA), were applied to the surroundings. Then, the Ti mesh and non-absorbable barrier-membrane were placed and were fixed using Bone Tack kit. Finally, a release incision to the lingual side mucosal membrane was added, which was stitched up for the completion of the surgery (Image-10). The secondary surgery to remove the titanium mesh and the barrier membrane were conducted 16 weeks later (Image-11 to 15).

The Periotest conducted three weeks after the secondary surgery was negative. Upon close inspection, the occlusal clearance was found to be lacking, therefore, impression was taken once No. 18 tooth had undergone a process of surgical crown lengthening (Image-16,-17). In order to limit the stress exerted on the implant and bone, aesthetic prosthesis with sinfony (3M) added onto metal coping was selected (Image-18,-19).

The radiograph taken 32 weeks later showed a satisfactory augmentation of the bone (Image-20).

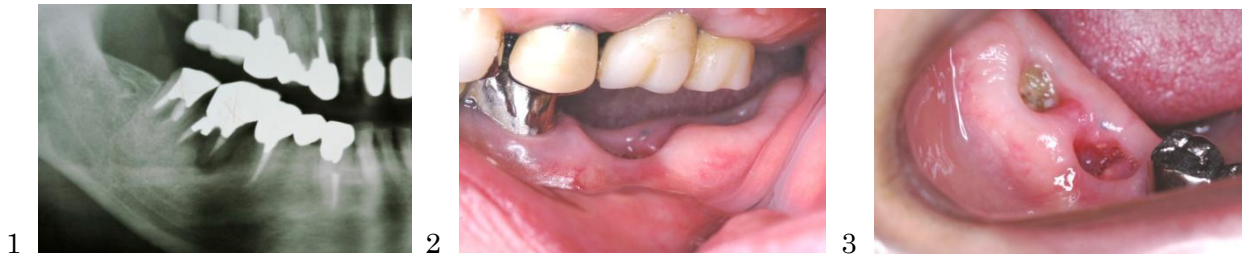

Image-1: Panoramic radiograph before tooth extraction. The lack of bone is particularly noticeable at No. 19 position.

Image-2,-3: The images of the occlusal plane and the lingual side after tooth extraction are shown. Low bone quantity can be predicted from the reduced height of the gingivae.

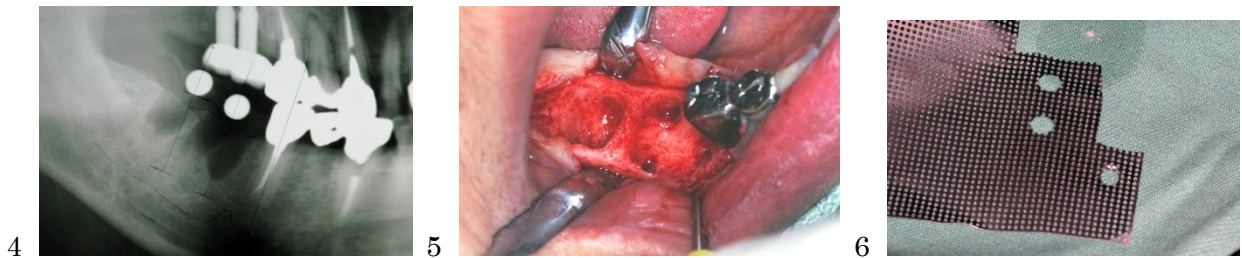


Image-4: Radiograph after the tooth extraction. Achieving primary stability with this bone quantity is likely to be problematic.

Image-5: Image of the extraction socket. A large cavity can be observed. The deficiency of the cortical bone on the lingual side of the No. 19 is particularly noticeable.

Image-6: A titanium mesh of 0.1mm thickness with 4.8 mm diameter hole carved out with a circular knife.

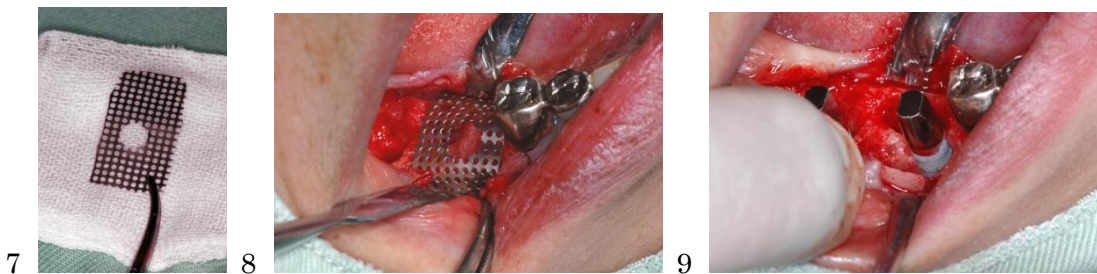
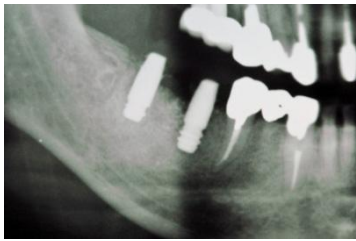


Image-7,-8: Titanium mesh that has been trimmed to fit at the implant site.

Image-9: Image showing the 5SS implant inserted into the position No.6. Unfilled space around the body can be seen.

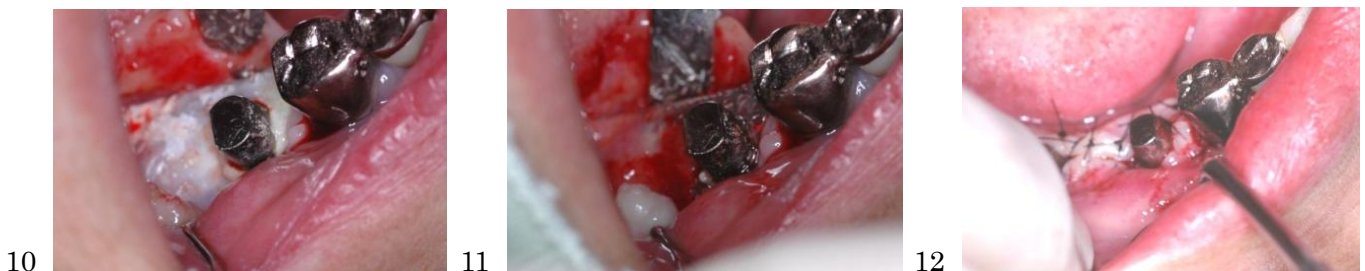

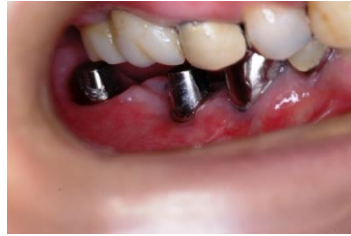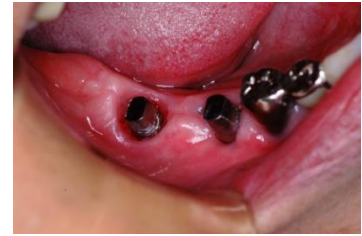Image-10,-11,-12: Image taken during the secondary surgery, performed 16 weeks after the primary surgery.



13



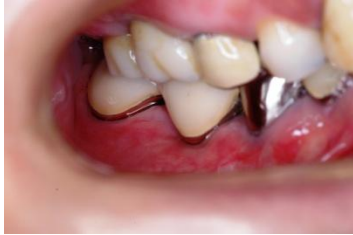14



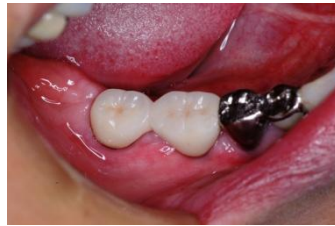15

Image-13: Radiograph featuring the state straight after the secondary surgery. It shows the space around the implant body to have been sufficiently filled.

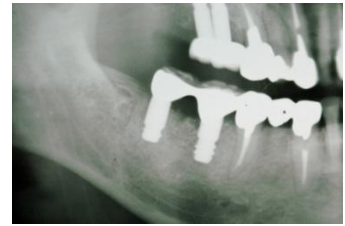
Image-14, -15: The surgical crown lengthening was conducted for No.17 tooth, after a space of only three weeks following secondary surgery. The length of the implant head was deemed suitable for maintenance.



16



17



18

Image-16,-17: Symphony (3M) was used on the type 4 platinum-gold alloy (PGA) prosthesis displays estheticism. (The image was donated by Dr. Okamoto, DC laboratory, Hamamatsu-city).

Image-18: Radiograph featuring the state, 50 weeks after completion of the treatment. Although some HA particles remain visible, the gradual maturation of the bone is also evident.

2. A case where GBR technique has been adopted for insertion of one-piece implant

General Manager of Department of Dentistry, Oral and Maxillofacial Surgery, Mitsui Memorial Hospital
Yasuhiko Tsuyama

When implanting into the mandibular molar region, one often comes across the state of the alveolar bones that have been severely affected by bone resorption on the buccal side, but absent on the lingual side. In such cases, it is usually solved by insertion of two-piece type, with a concomitant use of GBR technique. This option is associated with some disadvantages, including: long treatment periods that are often more than six months, and high cost due to uses of artificial bone and membrane materials.

Here we present a case whereby the treatment period was able to be shortened by the use of AQB one-piece type implant alongside bone transplant.

Patient: 58 year-old female

Chief complaint: To be treated so that she could also start chewing on the left side.

Medical history: Nothing to note

Current symptoms: No. 30 and 31 teeth affected by periodontal disease had been extracted.
Several dentures had been tried out however none of them could solve the lingering sense of discomfort.

Image-1 features the left mandibular molars. The buccolingual width can be seen to have been reduced, strongly suggesting that the alveolar bone on the buccal side to be resorbed. From this, it can be anticipated that the implantation procedure can be a complicated one. In Image-2 illustrates process of incision forming a mucoperiosteal flap, to expose the alveolar bone. The lingual aspect of the alveolar bone has been left unaffected, while the buccal side shows a complete resorption.

The drilled implanting cavity for a 4 mm diameter AQB Implant is shown in Image-3. At the time of drilling, a great precaution was taken to avoid causing any damages to the lingual aspect of the alveolar bone. Image-4 features size 4SM AQB one-piece implant inserted into the cavity. Although the HA coating layer on the buccal side is fully exposed, the primary stability was able to be achieved. The bone transplant was conducted to cover the part of HA coating layer that was exposed. Image-5 features the process of extracting the bone from the site surrounding the wisdom tooth. The cortical bone was extracted as a block. Images 6 to 9 feature the bone transplantation procedure to the site where HA coating layer was left exposed. The bone transplant was fixed with the natural bone on the mesial and distal sides of the implant. 4-0 nylon surgical thread was adopted for the fixture. The transplanted bone was covered with periosteum without the application of membrane, with the usual procedure (Image-10). The abutment space was filled with SuperBond adhesive two months later. The final superstructure with hybrid crown was placed two months after the implantation. Image-11 shows the state, after the placement of the metal bonded crown, with the attached gingivae has retrieved its position and Image-12 features the transplanted bone. Both these feature the state 6 months after the implantation. Visually, the newly transplanted bone appears to have the same consistency as the alveolar bone, and the HA coated layer to be covered adequately. The nylon threading that can be glimpsed is that used for the fixing the bone transplant and the natural bone.

Discussions: The requirements for a successful GBR method, using one-piece type are discussed below:

1. Securing the primary stability

To regenerate the bone successfully on the HA coating layer, it is essential to provide an environment whereby the stability of the implant body can be ensured. To achieve primary stability, the cavity should be constructed so that at least 3 mm of the base is covered with the alveolar bone on all four sides. For insurance, the initial fix should be reinforced with the use of SuperBond adhesives after the implantation.

2. Fixing of the transplanted bone

For a secure fix, titanium screw and microplate have been recommended to be used. In this example, the transplanted bone was fixed with nylon stitching. With nylon thread stitching, each threading holes must be made with certainty.

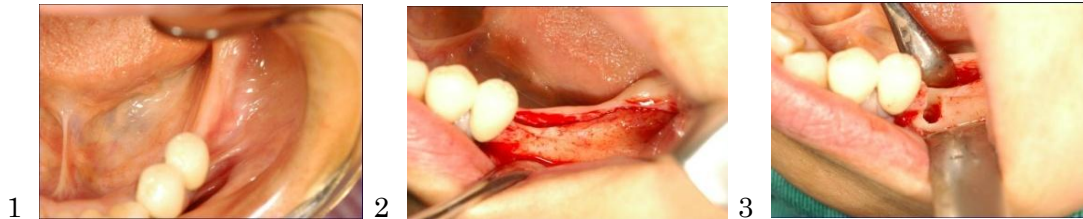

Image-1: Image of the left mandibular molars.

Image-2: Mucoperiosteal flap was constructed to expose the alveolar bone.

Image-3: Planting cavity was constructed.

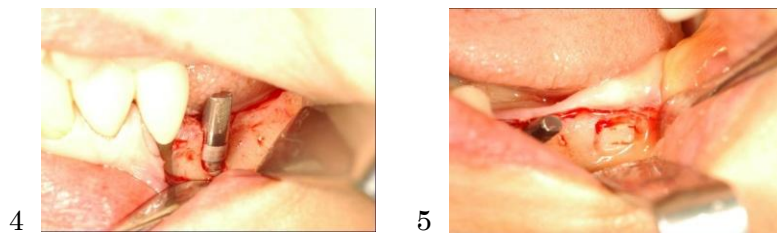


Image-4: Image of the oral cavity at the time of implantation. Even though the HA coating on the buccal side is fully exposed, primary stability could be established, and the bone transplantation was conducted to the exposed layer.

Image-5: Bone from the portion of the left mandibular wisdom tooth was extracted.

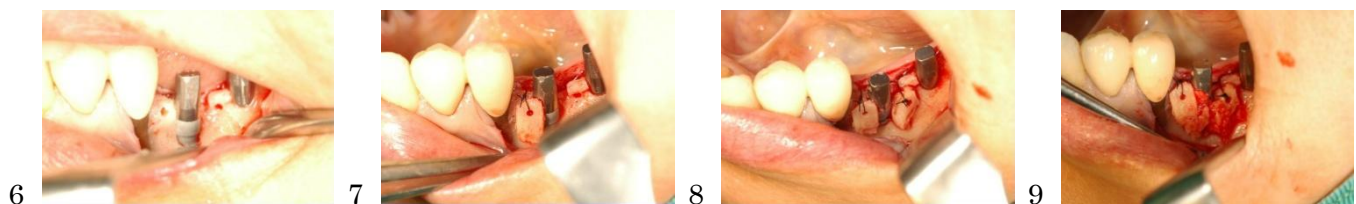


Image-6,-7,-8,-9: Bone transplant to the exposed HA coating layer.

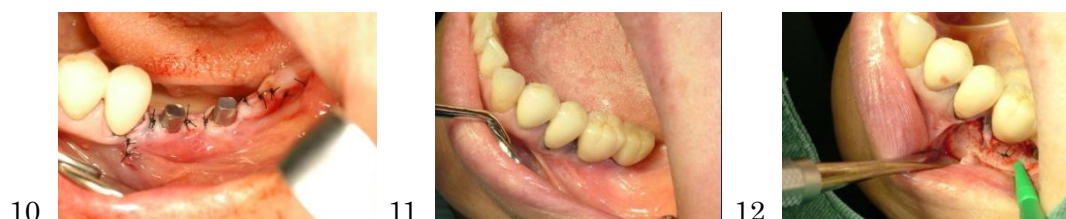

Image-10: Without application of the membrane, the transplanted bone was covered with the periosteum, and stitched up by the usual method of suture.

Image-11: Image of the oral cavity at the time of metal-bonded crown placement, 6 months after implantation.

Image-12: The state of the transplanted bone, six months after the implantation.

3. A case where the implantation immediately following tooth extraction with bone transplant.

General Manager of Department of Dentistry, Oral and Maxillofacial Surgery, Mitsui Memorial Hospital
Yasuhiko Tsuyama

At the planning stages of implant treatment, there are instances where the alveolar bone on the buccal side is absent due to bone resorption. In such cases, the usual treatment entails a given healing period to be arranged, and two-piece type implants are inserted, concomitantly applying GBR technique. This method has disadvantages such that the treatment period is often longer than six months, and the cost for the materials such as the artificial bone and membranes.

Here, a case is presented where the use of AQB one-piece implant with the concomitant application of bone transplant to the implant site led to shortening of the treatment period, achieving satisfactory alveolar bone regeneration.

Patient: 61 year-old male

Chief complaint: Pus is excreted from the position No. 5

Medical history: Nothing to note

Image-1 features the panoramic radiograph before surgery. The area surrounding No. 5 tooth is transparent, indicating that this would be a difficult subject for conservative therapy. It was extracted and the state of the oral cavity after this is shown here. The alveolar bone on the buccal side shows a complete resorption of the bone. As shown in Image-3, AQB Implant, 5ML, was implanted. Although the HA coating layer is exposed through to the base of the implant body, primary stability was able to be established with the three other sides. The bone transplant was conducted onto the exposed section. Image-4 shows the block of cortical and cancellous bone extracted from the left maxillary tuberosity portion. The extracted bone was subjected to the exposed layer of recrystallized HA coating, as shown in Image-5. It was stitched as to pressurize the transplanted bone to be fixed without any mobility. A satisfactory stabilization of the transplanted bone could be achieved therefore materials for further fixation such as microplate or nylon threading were not used. The transplanted bone was covered on top with the periosteum, without the application of the membrane, and stitched using the ordinary suture method.

The implant body was fixed using SuperBond with the neighboring teeth for a two months period. Occlusal loading was initiated following the implantation three months later with the use of provisional crown, and the final superstructure of metal bonded crown was set after a month, (four months since the implantation). Image-6 shows the state of the transplanted bone six months since the implantation of the body. No significant visual distinctions could be observed between the transplanted bone and the neighboring natural bone, indicating consistency in their degree of hardness. The HA coating layer was fully covered with sufficient bone quantity, and the alveolar bone on the buccal side had been completely regenerated.

The state of the oral cavity after a year and three months is shown in Image-7, where no gingival retraction can be observed. The state of the transplanted bone is shown in Image-8 taken around the same time period. The significance in the degree of proliferation of the bone surrounding the HA coating layer is clear when comparing the states before implantation and six months later,.

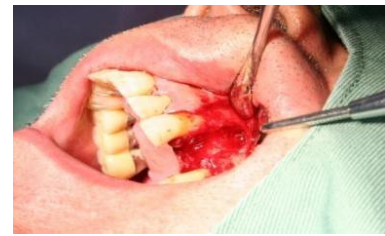
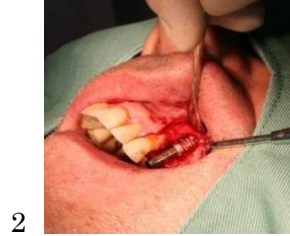
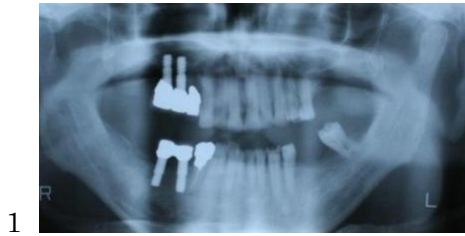Image-1: Panoramic radiograph before surgery

Image-2: Image of the oral cavity after tooth extraction. The alveolar bone on the buccal side shows complete resorption.

Image-3: Insertion of AQB one-piece implant, 5 mm diameter. The implant body is exposed on the buccal side to its base. The primary stability could be established with the three other sides.

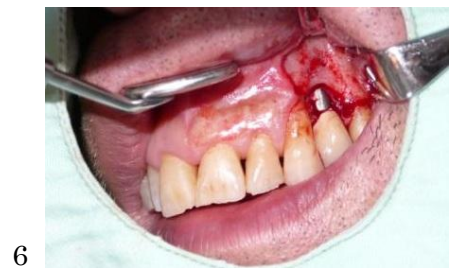
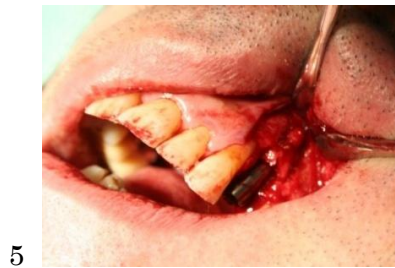
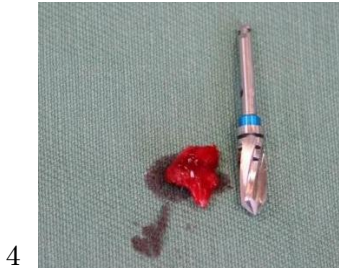Image-4: The bone, extracted from the left maxillary tuberosity.

Image-5: Bone transplant to the recrystallized HA coating layer.

Image-6: Image featuring the state of the transplanted bone. The transplanted bone has been visually converted to a hard bone that is of similar consistency to the neighboring natural bone, and the exposed HA layer had shown complete coverage with sufficient quantity of bone, and the alveolar bone on the buccal side had been fully regenerated.

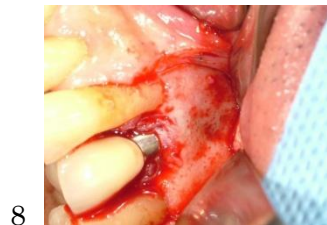
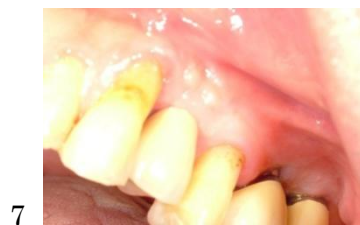
Image-7,-8: Image of the oral cavity after a period of 1 1/4 years, and the state of the transplanted bone. The bone regeneration is evident here.

4. A case where the implant treatment to the frontal maxilla, was conducted with autogenous bone graft, taken from the chin region.

Oral-Maxillofacial Surgery, Dentistry and Orthodontics,
The University of Tokyo Hospital

Yuki Kanno

Instructor of Oral-Maxillofacial Surgery, Dentistry and Orthodontics,
The University of Tokyo Hospital

Hideto Saijyo

The main problem with the implant treatment to replace the lost tooth as a result of atrophy of the alveolar bone is the lack of bone quantity. A case is presented, whereby the luxation of No. 9 and 10 teeth were replaced with the one piece implant (4 mm diameter) and once-piece T-type implant (3 mm diameter) after bone regeneration, under general anesthesia.

Patient: 60 year-old male

First admission: April 2008

Chief complaint: Loss of estheticism from lack of teeth that resulted from a fall.

Current symptoms: No. 9 and 10 teeth are missing, but without any problems regarding oral hygiene.

Treatment plan: Wait several months to allow wound healing, and analyze the bone quantity. If sufficient quantity of the bone is absent, plan an implant treatment with bone regeneration procedure.

At the time of primary medical examination, the frontal teeth had been luxated, the treatment was waited for three months till the wounds had healed. It was shown that the labiolingual bone width was insufficient (Image-1,-2), with only 2 mm from the alveolar ridge to the base when examined with a CT scan. Bone augmentation therapy was therefore conducted.

Bone augmentation therapy using autogenous bone graft was conducted under general anesthesia. This was five months after the injury. The incision was applied from the alveolar bone of the extraction socket to the tooth cervix of the neighboring tooth, and then to the oral vestibule (Image-4). Upon detaching the periosteum, the labiolingual alveolar bone was shown to be extremely narrow (Image-5). A piece of bone, extracted from the chin region, was reshaped and was placed on the lingual side of the alveolar ridge to fit the bone contours. This was finally fixed with microscrews.

Cancellous bone was compacted to the region where there were differences in their level between the natural and the transplanted bone (Image-8). The wound was closed after applying release incision to the mucoperiosteal flap, as shown in the postsurgical radiograph (Image-9,-10).

Three months after the bone graft operation, the surgical removal of the screw, and implantation was performed as an outpatient surgery under local anesthesia. Since there were no problems with the structure of alveolar ridge, in terms of the occlusion or the axial orientation of the type of superstructure that was planned to be used, one-piece type implant was selected.

With close inspection, the bone structure surrounding No.10 tooth had shown slight bone resorption as well as problem in the mesiodistal spacing with the teeth. Therefore, one-piece T-type with 3 mm

diameter was selected for implantation at this position. It was regarded that the use of T-type and the placement of a connected crown would relieve the occlusal force that could be exerted on the narrow, 3mm implant body.

Incision was made to the alveolar ridge, crossing to the cervix of the neighboring tooth. Although upon detachment, a slight bone resorption was revealed in a portion of the bone, there were no particular problems with the insertion of the implants that were originally planned (Image-11). As intended, 4MM implant to the position No. 9, and T3MS to No.10 were installed, and the treatment was completed (Image-12). The primary stability of both implants were able to be achieved, and there were no exposures of recrystallized HA coating.

Three months after implantation (Image-13), porcelain-bonded-to-metal crown was set after undergoing provisional restoration (Image-13).

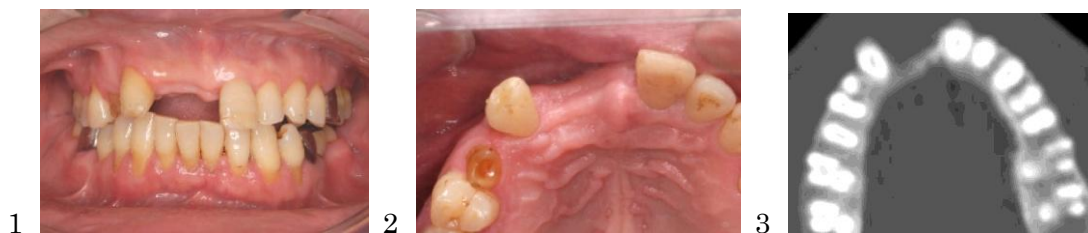

Image-1,-2: Image of the state before the bone augmentation therapy. Bone resorption, labiolingually to the alveolar ridge is evident.

Image-3: CT scan before surgery (Horizontal cross-section) showing a significant bone resorption in the area of No. 9 and 10 teeth.

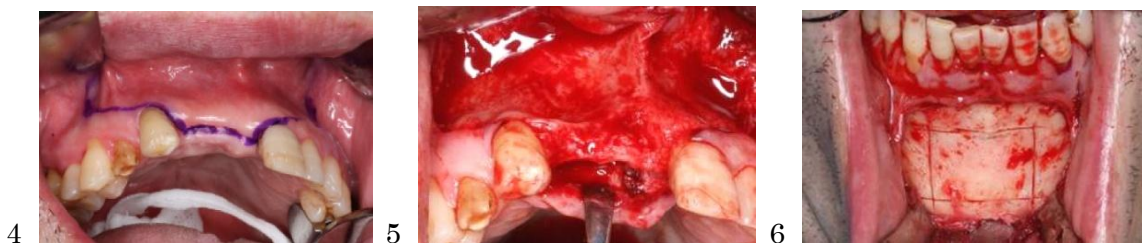

Image-4: Image of the oral cavity during bone augmentation procedure, with the incision line.

Image-5: Image of the state with periosteum detached. A significant bone resorption of the labial alveolar bone can be seen.

Image-6: Image after the osteotomy of the chin region

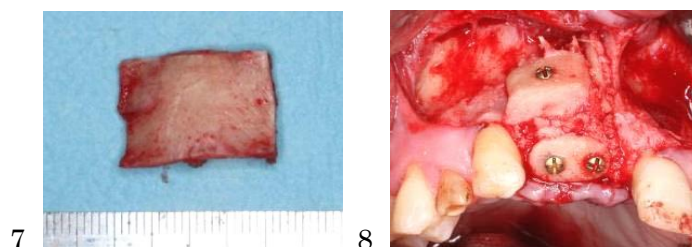


Image-7: Cortical bone that was extracted from the chin region.

Image-8: Cortical bone was grafted onto the labial side and the alveolar ridge, and cancellous bone was compacted onto its surroundings.

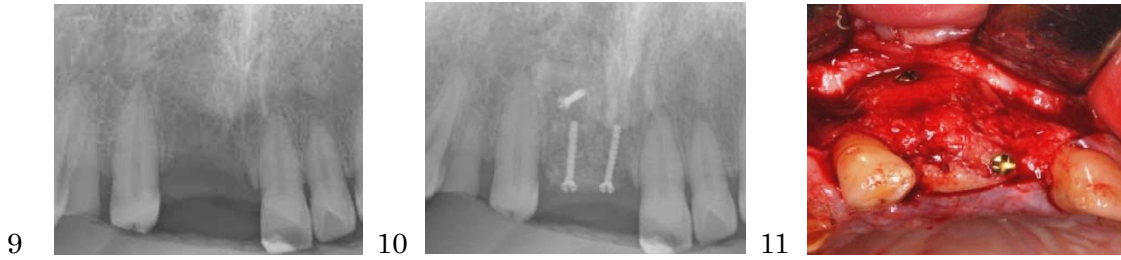

Image-9, -10: Dental radiograph, pre- and post-surgery. The transplanted bone shows satisfactory condition.

Image-11: Image during the implant installation. The bone regeneration was confirmed upon periosteal detachment.

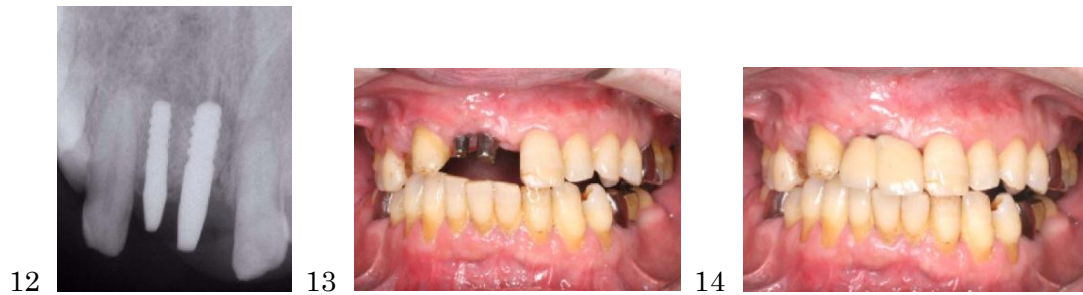

Image-12: Dental radiograph after implant installation.

Image-13: Image of the oral cavity, three months later

Image-14: A month after the placement of the porcelain bonded metal crown.

5. A case where implant treatment was conducted on the anterior maxilla, with autogenous bone graft with the bone extracted from the iliac bone.

Oral-Maxillofacial Surgery, Dentistry and Orthodontics,
The University of Tokyo Hospital

Yuki Kanno

Instructor of Oral-Maxillofacial Surgery, Dentistry and Orthodontics,
The University of Tokyo Hospital

Hideto Saijyo

The loss of anterior teeth due to occlusal damages can often be associated with problems such as lack of labiolingual bone quantity. In such cases, bone augmentation therapy may be required; however there are limits as to the bone quantity that can be extracted from within the oral cavity including the chin region. Iliac bone can be provided as an alternative for the transplantation to areas where a large amount of the bone is required to fill a large cavity, from which a sufficient quantity of both cortical and cancellous bone can be obtained.

Here, a case where the two-piece type implant was installed after autogenous iliac bone was grafted, under general anesthesia.

Patient: 55 year-old female

First admission: September 2007

Chief complaint: Loss of estheticism due to lack of anterior teeth. (The patient came to the clinic specifically requesting implant treatment).

Current symptoms: Lack of No. 10 and 11 teeth, and root of No. 9 remaining. Teeth No. 8 to 10 were fitted with temporary crown. Slight case of periodontal disease observed.

Treatment plan: Extract No. 9 tooth and then conduct alveolar bone augmentation therapy to the positions 9 to 11. Wait for the bone to integrate, and install two-piece type implants as a secondary surgery.

At the time of first medical examination, the lack of No. 10 and 11 teeth; as well as the state of No. 9 root were observed (Image-1,-2). The CT scan analysis showed the bone width to be merely 1 mm from the alveolar ridge through to the base, therefore the implant treatment was arranged to be conducted with bone augmentation therapy (Image-3). A periapical lesion, size of a rice grain, was found at No. 8 area, therefore apicotomy was planned to be conducted at the same time.

No. 9 tooth extraction, No. 8 apicotomy, and bone augmentation with autogenous iliac bone graft was conducted under general anesthesia. Upon detachment of the periosteum after the extraction of No. 9 tooth, the narrowing of the alveolar bone on the labiolingual side became apparent (Image-4). Apicotomy was conducted on No. 9 remaining root. The bone extraction for the transplant was conducted by forming a 30 mm skin incision to the interior of the anterior iliac crest on the right side, and the bone was extracted from lateral plate of the iliac crest (Image-5 to 9).

The natural bone was pierced through to induce blood supply (Image-10). The block of cortical bone extracted was reshaped to fit the deficient space on the buccal side, and was finally fixed with microscrews. The ridges generated between the grafted and the natural bone, as well as the area to which

the apicotomy was conducted, were compacted with cancellous bone (Image-11). The release incision was applied to the flap before closing the wound. The post-surgical radiograph is shown (Image-12).

Five months after the autograft, implantation was conducted after removing the microscrews as an outpatient, both under local anesthesia conditions. Two-piece implant was selected in anticipation of the difficulty in achieving implant primary stability, as the alveolar ridge has just been grafted, and for an esthetic recovery.

With satisfactory recovery made with the alveolar ridge, that had undergone bone augmentation process, (Image-13), two 4102 implants to No. 9 to 11 positions were installed undergoing the standard procedures (Image-14,-15).

The secondary surgery was conducted three months after the implantation, followed by provisional restoration after a period of wound healing. Lastly, the porcelain bonded-metal crown was placed as the final step (Image-16). This case actually had three teeth missing. However, prosthesis at this position with three implants was suspected to result in an unnatural profile due to the narrow mesiodistal width. Therefore to achieve esthetic recovery, only two implants were installed to this area.

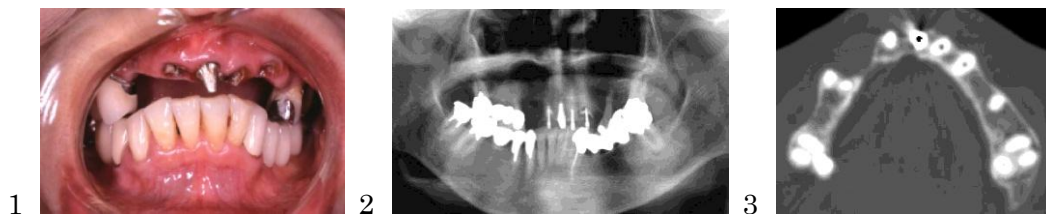


Image-1,-2: Image of the oral cavity, and panoramic radiograph at the time of primary medical examination.

Image-3: Pre-surgical CT scan (horizontal cross-section). Significant bone resorption on the buccal side of the alveolar bone on No.10, 11 positions are evident.

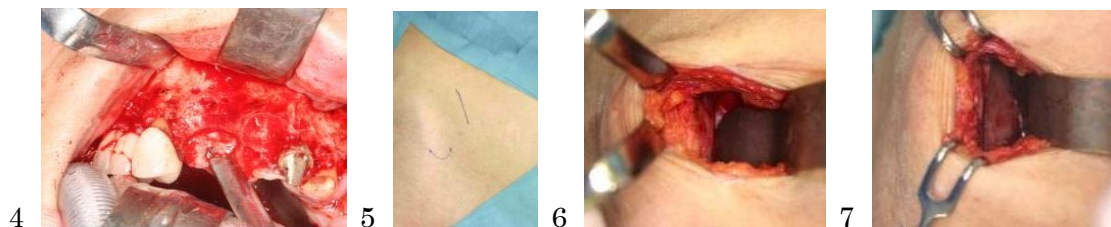


Image-4: The alveolar ridge with a knife ridge appearance, displayed after No.9 tooth extraction and periosteum detachment.

Image-5: Skin incision (approx. 30 mm) was marked on the inner surface of the right anterior iliac crest. The suture into this section was made with a No.15 surgical scalpel, followed by dissection of the layer of fatty tissues with an electrical scalpel to expose the aponeurosis. Then the aponeurosis was isolated with the electrical scalpel, and the iliac muscle and periosteum detached from the iliac crest interior.

Image-6: Traction of the iliac muscle to the centre after extracting the periosteum

Image-7: The cortical bone was cut out with a bone chisel from the lateral plate of the iliac crest.

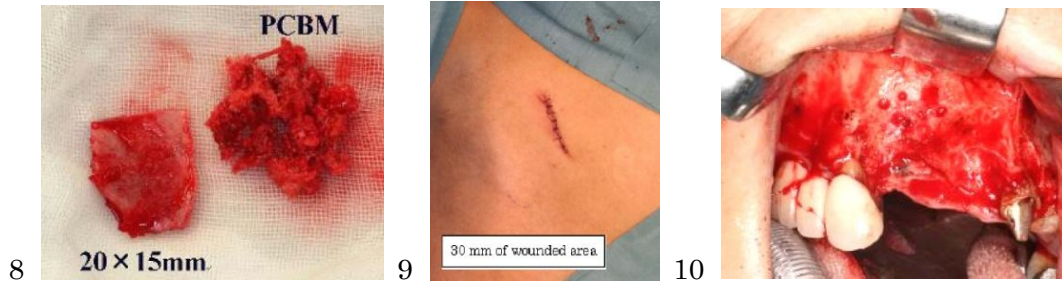

Image-8: Cortical bone with an area of: 20×15 mm was extracted.

Image-9: Image of the state after closing the wound. Stitching was done using 3-0 Vicryl® (Ethicon, a Johnson and Johnson Company) for periosteum, 4-0 Vicryl® (Ethicon, a Johnson and Johnson company) for the muscle layer, and 4-0 PDS II® (Ethicon, a Johnson and Johnson company) for dermis, and 5-0 nylon for epidermis.

Image-10: The natural bone was pierced through to generate blood supply to the grafted bone.

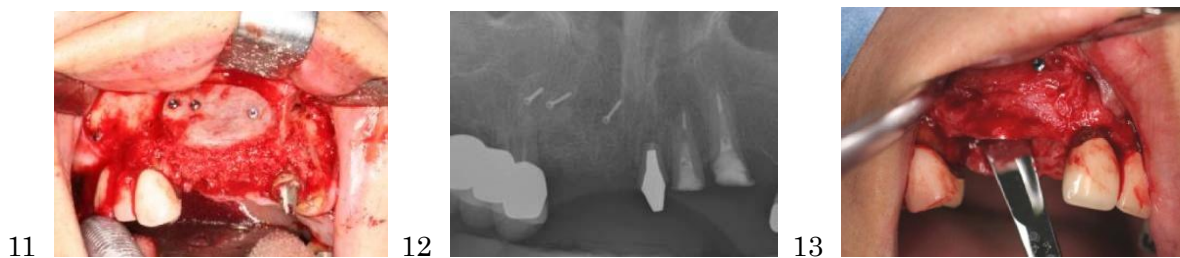

Image-11: The cortical bone was transplanted on the buccal side. Cancellous bone was compacted to the remove the edges between the surfaces of the natural and grafted bone and to the area in which apicotomy was conducted.

Image-12: Post-surgical panoramic radiograph

Image-13: Image at the time of implantation. Satisfactory bone regeneration could be observed upon detachment of the periosteum.

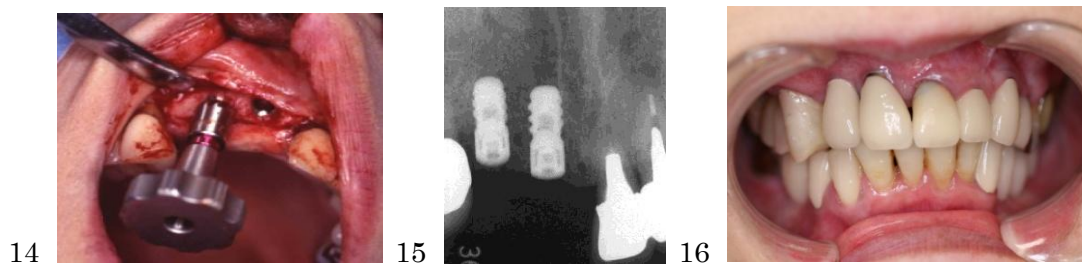


Image-14: Image taken at the time of 4102 fixture placement.

Image-15: Post-surgical dental radiograph

Image-16: Image featuring the state a year later, with the placement of the porcelain bonded metal crown.

6. A case where implant treatment was conducted to replace a tooth loss for occlusal recovery, after application of bone augmentation procedure.

Oral-Maxillofacial Surgery, Dentistry and Orthodontics,
The University of Tokyo Hospital
Nobuko Hayashi
Instructor of Oral-Maxillofacial Surgery, Dentistry and Orthodontics,
The University of Tokyo Hospital
Hideto Saijyo

Bone transplant is often required to reconstruct the bone in preparation for implant treatment to areas where there is inadequate alveolar bone quantity.

There are two types of bone extraction means for bone graft: intra- and extra-oral, and the amount of the bone required would determine where the bone would be extracted from. If a large quantity is required, the bone would be extracted from an extra-oral source (mainly iliac bone) but for those areas where slight reconstruction is needed, a piece of bone can be extracted from intra-oral source.

A case is presented where implant installation was conducted for the tooth loss resulting from an injury, with bone augmentation procedure.

Patient: 23 year-old male

Chief complaint: Masticatory disorder due to the loss of mandibular premolars.

Medical history: Multiple fractures in the face resulting from a car accident. Undergoing open reduction and internal fracture (ORIF) surgery. Also lost No. 4, 5, 7, 8, 9, 10, and 13 teeth in the accident.

Current symptoms: Loss of No. 4, 5, 7, 8, 9, 10, and 13 teeth. Roots of No. 6, 11 and 12 that had lost the crowns were chosen to be preserved (Image-1,-2).

Treatment plan: Conservative treatment was conducted to No. 6, 11 and 12 teeth, and a bridge was fabricated to link No. 6, 11 and 12 teeth. After the bridge placement, implant prosthesis was planned to be installed onto No. 4, 5, and 13 positions. The alveolar bone on both sides of the jaw were discovered to have thinned, with the labiolingual width to be insufficient, the usual implant method could not be conducted. Therefore, bone augmentation procedure was planned to be conducted using bone from the chin region before the implantation.

This autogenous bone graft was conducted under general anesthetic conditions. After forming pores to the grafting region with a fissure bur (Image-4), the block of cortical bone that was extracted from the chin region was placed on the buccal side of the thinned alveolar bone in a way that fitted with the state of the bone that lacked teeth (Image-3). The cortical bone block was fitted on the buccal side, fixed with microscrews, and the spaces between the bones were compacted with cancellous bone and cortical bone to smooth out its form.

Ten months later, implantation was conducted to the No. 13 position after the microscrew removals from the right side of the jaw. Due to the presence of dehiscence on the mucosal membrane, grafted bone had resorbed after the surgery. Two-piece, one-stage implant with 4102 fixture was selected in anticipating the difficulty with which to achieve primary stability in this treatment area (Image-7d). One-piece

implant was installed to the left side where there were no apparent problems arising. Implants of size 3MS to No. 5, and 4MS to No. 4 position were installed as had been chosen at the primary assessment stage (Image-7a, b, c). The primary stability could be achieved on both sides, therefore no additional modifications such as fixation of implant body or connecting the structures were unnecessary (Image-8-a,b). Three months following implant installation, a porcelain bonded metal crown was placed as the final superstructure after undergoing provisional restoration (Image-9).

Improvements in the masticatory functions and esthetics have been noted, and satisfactory progress has been made even after five years from the primary surgery.

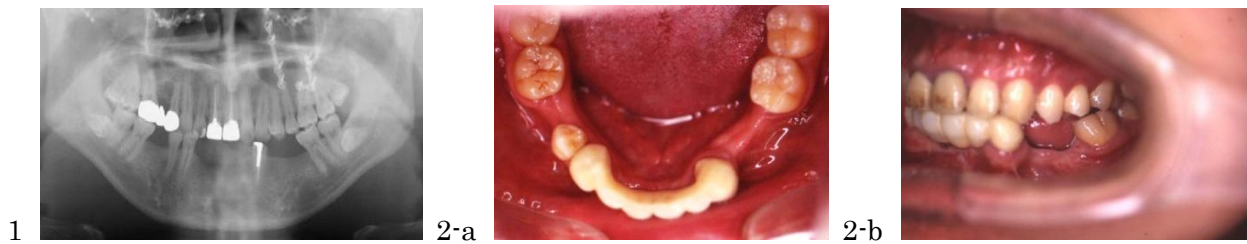


Image-1: Panoramic radiograph at the primary clinical examination.

Image-2a, b: Images of the oral cavity at the primary clinical examination.

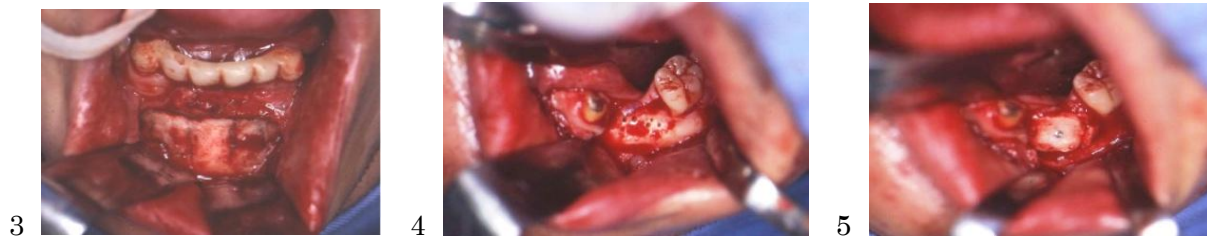

Image-3: Image featuring the extraction of the bone from the chin region

Image-4: Image featuring the formation of the pores to the portion of the alveolar bone. The blood flow in this region was confirmed, and showed a satisfactory flow.

Image-5: Post-surgery

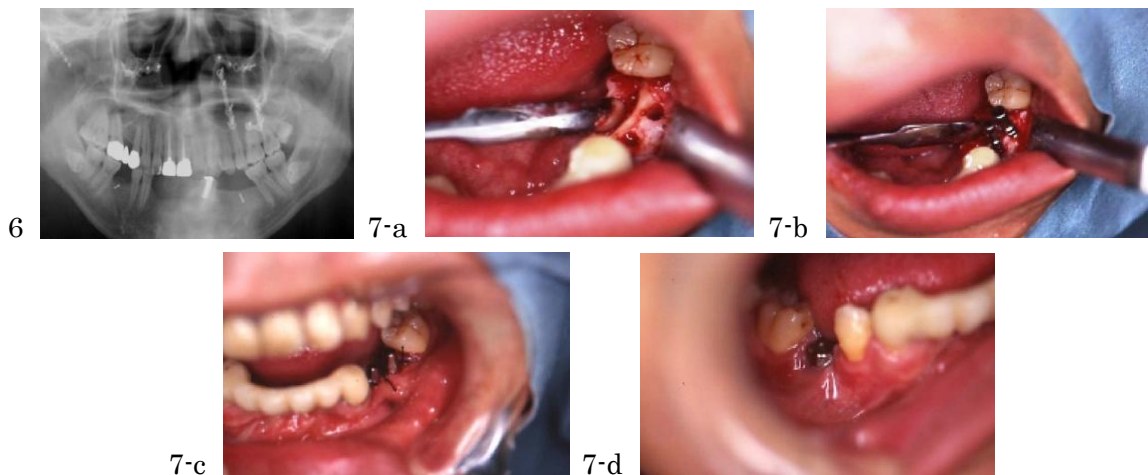
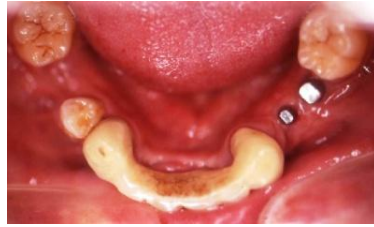
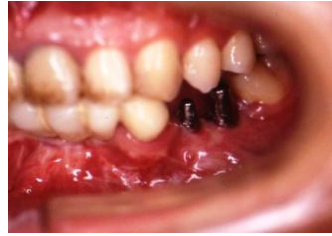
Image-6: Post-surgical panoramic radiograph

Image-7a,b,c,d: Images at the time of implant installation.

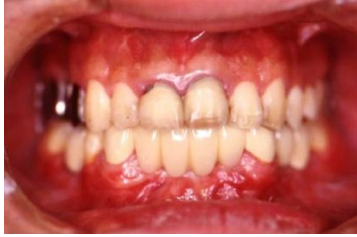

8-a

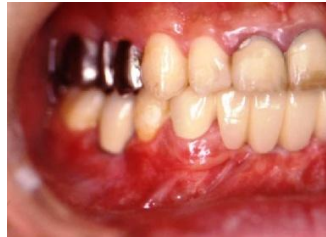

8-b

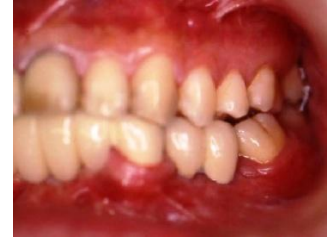Image-8a,b: Images after the implant installation



9-a



9-b



9-c

Image-9:a,b,c Image at the time of the placement of the porcelain bonded metal crown.

7. A case where the bone augmentation procedure was conducted using titanium mesh to the section of missing teeth on the anterior section of the mandible.

The University of Tokyo Hospital

Yuki Kanno

Instructor of Oral-Maxillofacial Surgery, Dentistry and Orthodontics,

The University of Tokyo Hospital

Hideto Saijyo

A sufficient quantity of the alveolar bone is required for implantation. There are several means in bone augmentation procedures that are required to be conducted to meet this requirement. Such methods include: block bone graft, methods that use titanium mesh plate or membranes, and those that use bone filling agents (artificial bone).

Here, a case is presented whereby concomitant application of block bone graft and titanium mesh plate was used as a bone augmentation method to repair the alveolar bone loss that resulted from injury.

Patient: 20 year-old female

First admission: January 2004

Chief complaint: Loss of estheticism due to lack of anterior teeth in the mandible.

Medical history: Traffic accident when 15 (Image-1). Multiple fractures to the face, and have undergone several surgical operations including: ORIF procedure and cranioplasty (artificial bone graft). The teeth that are not subjected for implant treatment also have faults, and the crowns have been restored as a means of conservative treatment.

Current symptoms: Loss of No. 6 to 9 teeth which have been placed with provisional denture in preparation for the implant treatment after the end of her growth development.

Treatment plan: Due to lack of vertical bone quantity (Image-2, -3), bone augmentation procedure was required to facilitate implantation. A prosthetic treatment with two-piece implant was planned after the augmentation procedure.

Iliac bone graft was conducted. The incision line was drawn on top of the cicatrix (Image-4). The detachment of the periosteum revealed a heavy vertical bone resorption of the alveolar bone (Image-5). Cortical bone block was grafted onto the alveolar ridge for a vertical restoration, and was fixed with microscrews (Image-6). The gaps between the bones were compacted with cancellous bone (Image-7), and a release incision was applied before closing the wound. The post-surgical panoramic radiograph and 3D CT scan are shown (Image-8,-9).

Four months after the bone graft surgery, implantation was conducted after screw and titanium mesh removal, under infusion of local anesthesia. Upon removal of the titanium mesh, the state of bone adhesion appeared to be satisfactory (Image-10), and the implantation was able to be conducted in accordance with the original plan (Image-11,-12).

Secondary surgery was performed seven weeks later. Custom-made abutment was fabricated (Image-13, -14) and was fitted with porcelain bonded crown (Image-15). Reduction in the area of the oral vestibules was observed, but favorable state of hygiene, and peri-gingival conditions were found.

Bone augmentation procedures are essential requirements in the areas where significant vertical bone resorption exists. As in this case study where bone resorption has affected large area, it is difficult to

ensure safety and sufficient restoration with artificial bone as the transplant material. In bone augmentation procedures where the aim is to achieve a sufficient level of bone width, concomitant application of titanium mesh could be constructive to retain its structure, even for cases of autograft. Another important point to note is the treatment of the mucosa. Attention should be paid even after wound has been sewn up, due to common incidences of dehiscence, and reduction in the oral vestibules occurring. One should bear in mind the possibilities of these complications and should be prepared to conduct vestibuloplasty if these do indeed arise.

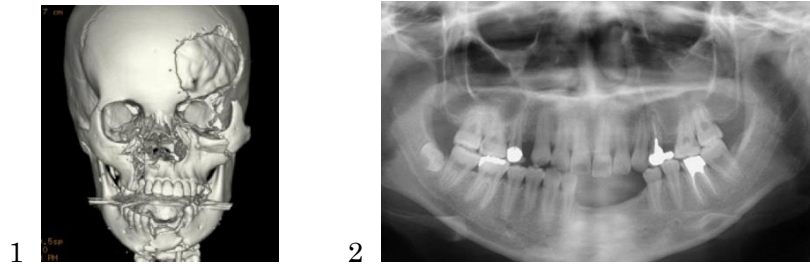


Image-1: 3D CT scan taken at the time of the first clinical examination

Image-2: Panoramic radiography before the bone augmentation procedures.

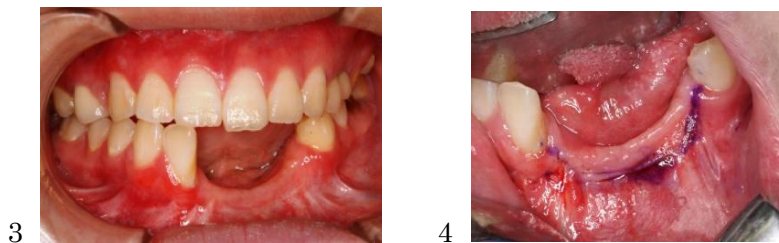


Image-3: Image before the bone augmentation therapy. A significant vertical bone resorption is apparent.

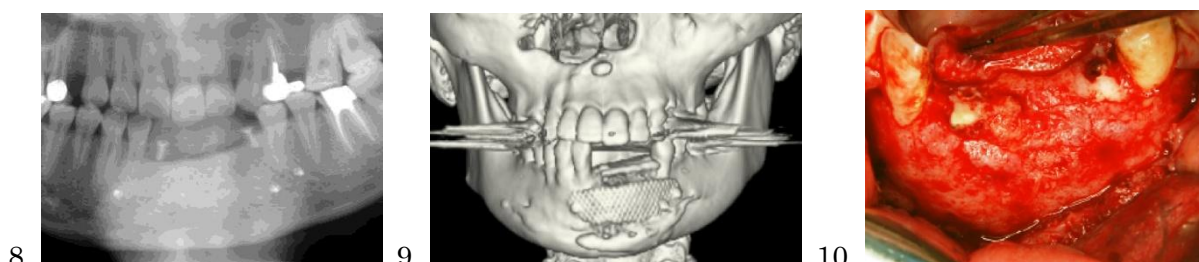
Image-4: Image before the bone augmentation therapy. Incision line was drawn on top of the cicatrix.

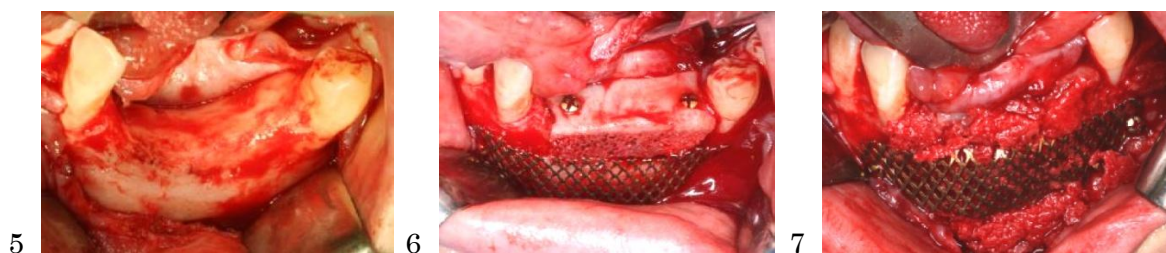

Image-5: Image during the bone augmentation therapy. Detachment of the periosteum revealed a significant vertical bone resorption.

Image-6: Image during the bone augmentation therapy. Extracted bone block was grafted onto the alveolar ridge and the titanium mesh plate to the labial side.

Image-7: Image of the state during the bone augmentation therapy. Cancellous bone was compacted into the gaps in bones.



8

9

10

Image-8,-9: Panoramic radiograph and 3D CT scan after the bone augmentation procedure. The bone graft onto the alveolar ridge and the titanium mesh plate on the labial side are observed.

Image-10: Image taken during implantation. No exposure of the titanium mesh plate, and the adhesion of the bone showed satisfactory outcome.

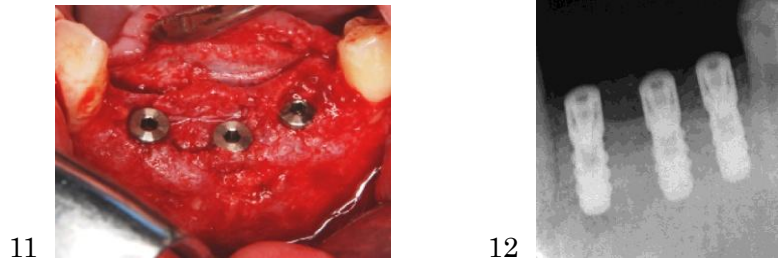


Image-11: Image taken during implantation. Three 4102 fixtures were inserted. No signs of HA coating layer exposure.

Image-12: Dental radiograph taken during implantation confirming that the implants could be inserted to the planned positions.

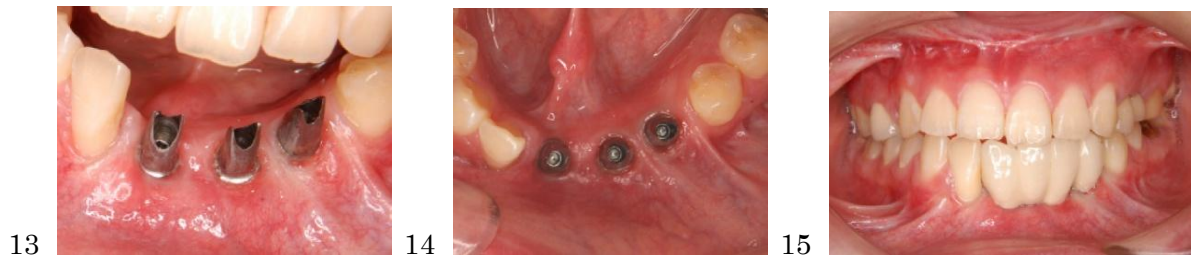

Image-13, 14: Image of the oral cavity after the placement of the custom-made abutment.

Image-15: Image of the porcelain bonded metal crown fitted.

8. A case in which bone filling agent, platelet rich plasma (PRP) therapy and titanium mesh plate (TIME) were applied.

Professor of Dental Surgery, The Nippon Dental University Hospital

Masayori Shirakawa

Instructor of Dental Surgery, The Nippon Dental University Hospital

Hirobumi Shoji

Kumasaka – Dental. Office

Hisao Kumasaka

Patient: 44 year-old male

Chief complaint: Masticatory disorder.

Medical history: Nothing to note

Current symptoms: Nothing in particular to note. No. 5 and 6 teeth were lost.

Radiographic observation: Nothing to note

Treatment and progress

Effects of bone resorption could be observed on the buccal side in this example. First, impression was taken, and modeled with investigation model with an ideal occlusion to assess the best implant position. The analysis indicated the high probability of the implant being exposed (Image-1,-2,-3) therefore GBR with the addition of bone filling agents and PRP therapy were chosen to facilitate the implantation procedure.

The suture method was conducted in the following order: first, incision was made on top of the alveolar ridge, which was then extended through the tooth cervix from No. 3 to 6 position, before forming a mucoperiosteal flap to expose a sufficient area of bone (Image-4). As expected, the significant amount of alveolar bone had been affected. The AQB implant cavity was constructed and expanded following the ordinary surgical procedures (Image-5). AQB implant type 4102 (Total length 10 mm), and 5122 (Total length, 12 mm) were adopted for this example. These implants were placed into the oral cavity with healing caps. Implants were then inserted using SOL driver bit to the positions where the portion of the interlock would sit above the edge of the bone but the coated layer would not be exposed from the bone, ideally (Image-6). As expected however, the implant coating installed in No. 4 position was exposed on the buccal aspect. GBR was adopted with the application of PRP to β -tricalcium phosphate (β -TCP, Bioresorb, Oral Tronics).

Forty ml of venal blood collected from the patient was subjected to centrifugation (Heraeus). Following the instructions of the manual, serum and platelets were harvested before being subjected to second centrifugation. By combining a sufficient quantity of the extracted PRP to 0.5g of bone filling materials, the mixture could be obtained in its gel-form (Image-7). Amount of bone filling agent sufficient to cover the coating layer was applied, to which PRP was added in drops (Image-8). The titanium mesh was applied in a way to preserve the treatment area, and was fixed with titanium bone tack (Image-9). Finally, the mucoperiosteal flap was restored back to its original position, and to which a release incision was applied before closing the wound completely (Image-10).

Secondary surgery was performed four months later. As with the primary surgery, incision was formed on

top of the alveolar ridge, as well as a longitudinal incision to expose the healing cap and titanium mesh. With the aid of HEX driver bit, healing caps were removed and were replaced with healing abutments (Size M for both No.4 and 5 positions). Next, the titanium pin and the titanium mesh were extracted with the tweezers designed specifically for this purpose. A vigorous bone augmentation was evident underneath the mesh, indicating the high efficacy of GBR with use of PRP therapy. The portion of the gingivae corresponding to the projection of the healing abutment was curved out using the circular scalpel before stitching to complete the secondary operation.

Impression was taken using a closed-tray method a month after conducting the second surgery. This was done using the personalized tray fabricated with the snap impression taken before the surgery.

The exchange of healing abutment with a multi-abutment was done intraorally (Image-11) to which, the pick-up impression coping was firmly fixed onto the abutment (Image-12). With the aim to strengthen the fixture and to improve reproducibility, the two pick-up impression copings were connected and fixed using pattern resin.

Silicon impression agent was pasted onto the inner and outer surfaces of the pick-up impression coping, and impression was taken with the personalized tray that had been previously prepared (Image-13). Once the impression agent had set, and the tray had been removed, the pick-up impression coping was found remaining in the impression material (Image-14). Multi-abutment was removed from inside the oral cavity, to which an implant analogue was firmly fitted. This was restored into the pick-up impression coping that was present within the impression agent (Image-15). In an attempt to duplicate the gingivae structure, the gum impression agent was added to the level of interdigitation. The model was completed by finally pouring in the plaster after the agent had set (Image-16).

The modeling indicated the ideal abutments at these positions would be straight-abutment M and S (Image-17). As for the superstructure, connected metal-bonded crown was chosen (Image-18). The final prosthetics were placed two weeks after taking the impression (image-19). The esthetic recovery requested by the patient was met with undergoing these processes (Image-20).

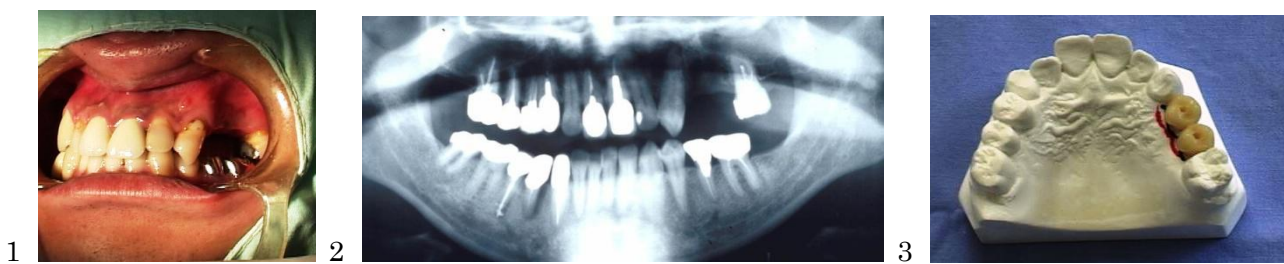

Image-1: Image of the state before surgery.

Image-2: Panoramic radiograph before surgery.

Image-3: Preoperative modeling of the intraoral cavity.

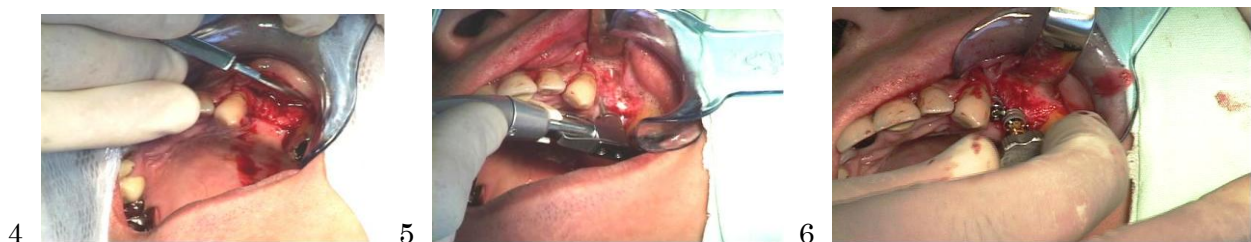

Image-4: Image of the state during surgery. The suture was applied in line with the tooth cervix, to allow sufficient view of the bone.

Image-5: The implant cavity was constructed and expanded with the usual means.

Image-6: The implants were placed to avoid exposure of the HA coating but could not prevent a portion from being uncovered.

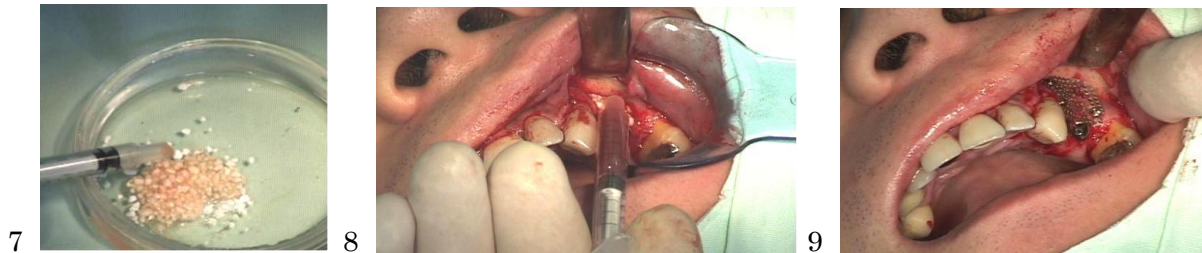

Image-7: Gel-like mixture of bone filling agent immersed with PRP.

Image-8: Further application of PRP.

Image-9: Fix with the titanium bone tack.

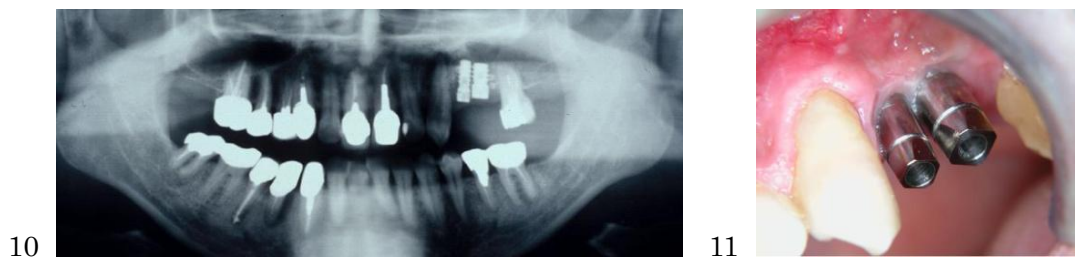

Image-10: Panoramic X-ray after the placement of two-piece implant.

Image-11: Placement of the abutment at the secondary surgery

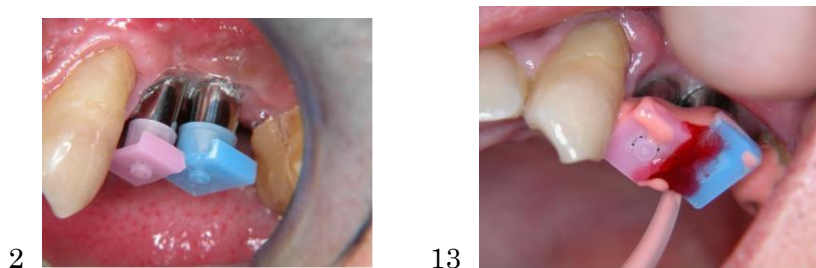


Image-12: Firm fixation of the pick-up impression coping

Image-13: Fixing two pick-up impression copings with pattern resin.

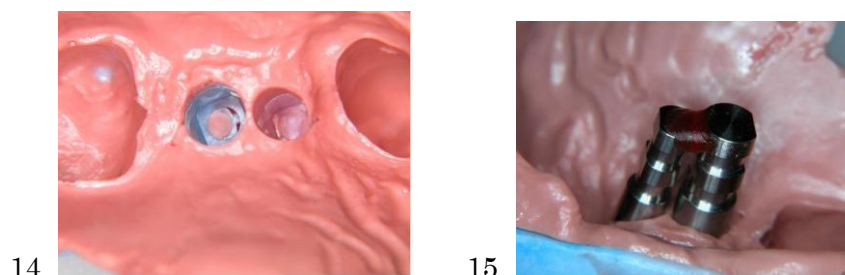


Image-14: Impression taken with the personalized tray that had been initially fabricated. Upon removal of the impression tray, the pick-up impression coping can be found to be removed attached to the hardened impression tray.

Image-15: Removal of the multi-abutment from the mouth, and fixed this with the implant analogue. Restore this to the pick-up coping in the impression agent.

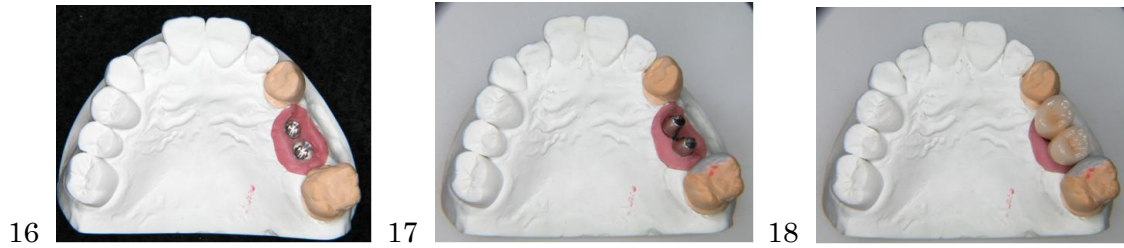

Image-16: Pour the impression agent up to the level of interdigitation, and upon its settlement, pour plaster to complete the model.

Image-17: Straight-abutment M and S were selected.

Image-18: Connected metal-bonded crown was chosen as the superstructure.

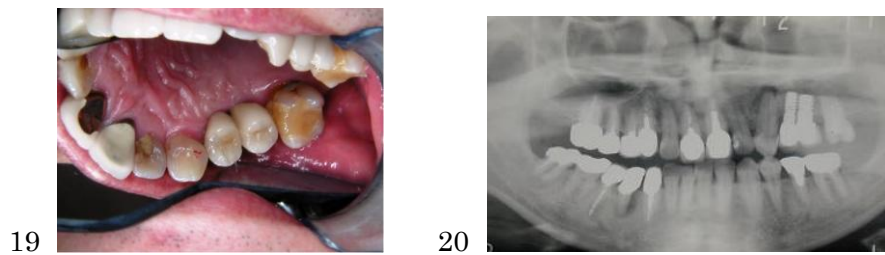


Image-19: Final superstructure was placed, two weeks after the impression taking.

Image-20: Panoramic radiograph after the placement of the final superstructure.

9. A case where the bone augmentation was applied, adopting PRGF method in a GBR case example.

Director of Kashima Dental Clinic

Kenji Kashima

Plasma rich growth factor (PRGF) technique, developed by Biotechnology Institute (BTI, Spain) is a novel system that uses the growth factors included in blood platelets to accelerate tissue regeneration. The notable improvement from the PRP therapy that has been commonly used in the past is the enhanced reliability with which alveolar bone regeneration is conducted.

Here, a case is presented whereby PRGF was applied to facilitate implantation of AQB one-piece type, 468, to a position where the bone quantity was insufficient, and with short distance to the maxillary sinus.

Patient: 48 year-old male

First admission: November 2008

Chief complaint: Requested placement of the bridge to the extraction socket on the right maxilla.

Treatment plan: Install two implants to positions No. 13 to 15, to be fitted with bridge prosthesis.

No. 15 tooth had been placed with a full cast crown, and metal bonded bridge to No. 10 and 11, No. 7 and 8, as well as No. 2 and 3 (Image-1,-2). The bridge on the right hand side had been placed with a strain, therefore had been the subject of multiple failures, and had to be re-fitted every time it fell out.

At the time of pre-surgical consultation, the application of PRGF technique was decided upon prior to the implant insertion, instead of sinus lift technique. The decision was based on consideration of the bone width to the maxillary sinus that was 6 to 7 mm, and its structural form.

First the venous blood of the patient was collected, and was subjected to centrifugation under the PRGF system (Image-3). Then the third fraction of the supernatant was collected to be applied onto the implant body (Image-4), and to the drilled implant cavity. The first and second fractions were hardened with heat treatment and were placed as an adjuvant form to the bone surrounding the implant before closing the wound (Image-5,-6,-7).

The application of PRGF resulted in accelerating the healing of the gingiva, enabling early placement of the superstructure. Impression was taken seven weeks after the implantation, and the superstructures were set after the fitting trial with the metal crowns (Image-8,-9,-10,-11,-12,-13).

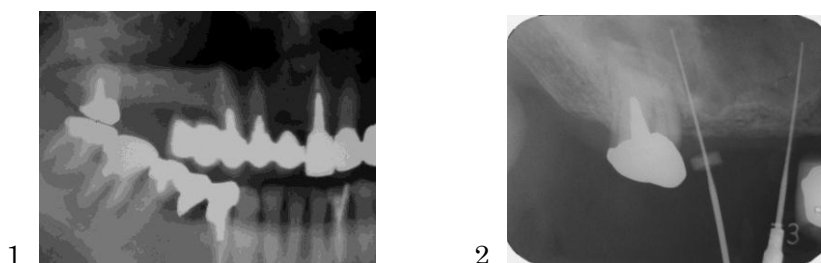


Image-1: Pre-surgical panoramic radiograph. The bridge that had been placed on No. 10, and 11 teeth had been highly unstable and often were subjected to sliding, therefore the patient had considerable difficulty in chewing with the right side.

Image-2: Dental radiograph before surgery. At the time of taking this picture, the pontics that is usually placed on No. 12 and 13 are not present due to patient's request. The distance to the maxillary

sinus was found to be roughly 6 mm, when determined using the probes.


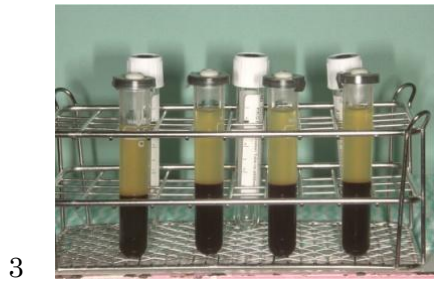


Image-3: Venal blood that was subjected to centrifugation using the PRGF protocol.

Image-4: Venal blood separate into three fractions.

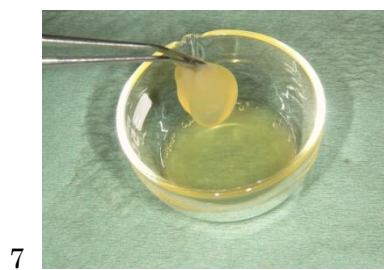
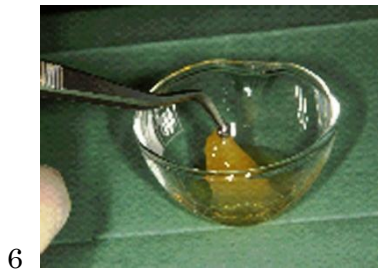
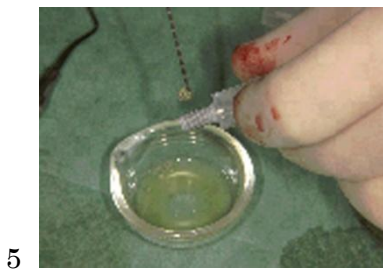
Image-5: Fraction 3 was applied onto the implant.

Image-6,-7: Fractions one and two were hardened with heat treatment, and was placed on the alveolar ridge, as a single layer, before closing the suture.

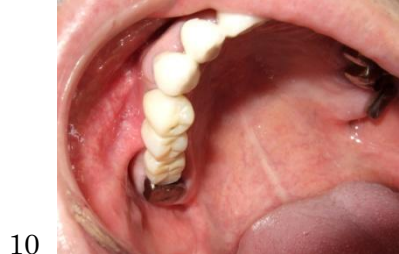
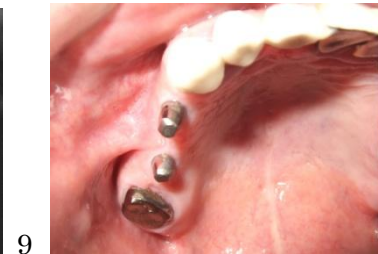
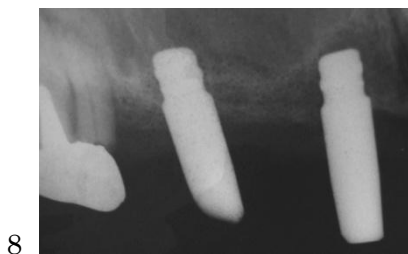Image-8: Dental radiograph straight after the implant.

Image-9: Image of the oral cavity, six weeks after surgery.

Image-10: Placement of the superstructure.

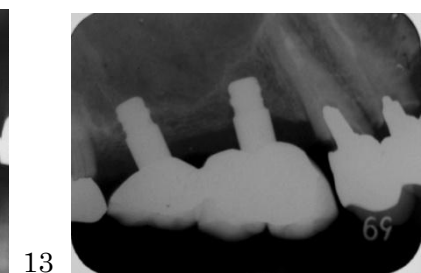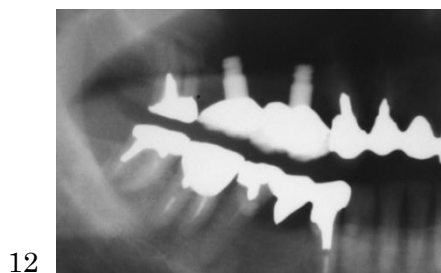

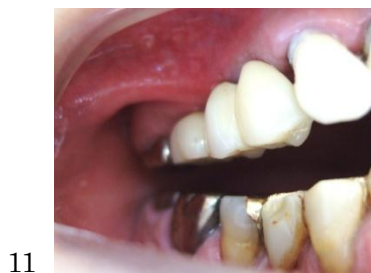
Image-11: Bridge was placed onto the implant installed at the positions No. 12 and 14.

Image-12: Panoramic radiograph after the placement of the superstructure.

Image-13: Dental radiograph taken two weeks after the placement of the superstructure.

10. A case where two-piece implants were installed to the anterior region of the mandible severely affected with bone resorption – Alveolar bone augmentation was conducted with concomitant use of GBR method, performed without autogenous or artificial bone graft.

General Manager of Department of Dentistry, Oral and Maxillofacial Surgery, Mitsui Memorial Hospital
Yasuhiko Tsuyama

Anterior teeth loss of the mandible is often subjected to significant bone resorption. Such cases are usually solved by conducting bone graft or by extending the alveolar bone, but the increase in the degree of surgical invasion is inevitable. The current task is to reduce the number of surgical trauma. Here, a case is presented where a satisfactory implant treatment could be achieved with concurrent use of GBR method for alveolar bone regeneration, performed without autogenous or artificial bone graft.

Patient: 63 year-old female

Chief complaint: Requested insertion of implant to the anterior section of the mandible.

Family medical history: Nothing to note.

Current symptoms: Presented with loss of No. 7 to 10 which were extracted a year ago due to effects of periodontal disease. Partial dentures had been placed with partial dentures, however due to sense of discomfort, requested implant prosthesis.

Image-1,-2 show the state of the anterior mandible. The narrowing in terms of the labiolingual width and vertical bone resorption can be observed. Image-3 features where the mucoperiosteal flap is curved out for the exposure of the alveolar bone. The lingual portion of the alveolar bone shows some remaining while the labial portion shows complete resorption. Inserted AQB two-piece implants, of 4mm diameter, are shown in Image-4. Even though the HA coating on the labial side was left completely exposed, primary stability could be achieved. Release incision was applied to the mucoperiosteal flap on the labial side as shown in Image-5. Next, the membrane (Gore-Tex, TR6) was applied to cover the HA coating completely (Image-6). Bone or artificial bone graft were not performed here. The mucoperiosteal flap was recovered to its original position and sutured with the 4-0 surgical thread, having covered the membrane (Image-7). This was left to heal for 4 months, protected with temporary crown (Image-8). The images of the state during the healing process is shown in Images-9 and -10. The state underneath the membrane, as shown in Image-11, the implant body has been covered with neonatal bone. With the placement of abutment, its stability was monitored for six months, protected with the application of temporary crown. With good progress made, and no apparent bone resorption, metal bonded crown was placed as the final prosthesis (Image-12).

The favorable condition of the treated region after two years (Image-13) lacking any complications that are commonly associated such as gingival constrictions.

Discussion – [Key to a successful AQB two-piece implantation with GBR method that does not apply autogenous or artificial bone graft]

① Accurate release incision and suture

The common complications that result from the membrane exposures can be overcome with the

means of release incision and suture. These two factors hold the keys to a successful treatment. By forming a well-defined release incision, the mucoperiosteal flap can be restored to its original position without any strain. The common complication of ischemia resulting from excessive tightening of the suture can easily be overcome with the application of face-to-face suture.

② Securing and retaining the space around the implant

In order to maximize the osteoinductive ability of HA coating layer, providing sufficient space and maintaining this are crucial. Membrane that consisted of titanium was used in this example, and considerations to the methods to stabilize the membrane firmly to stop it from moving are required.

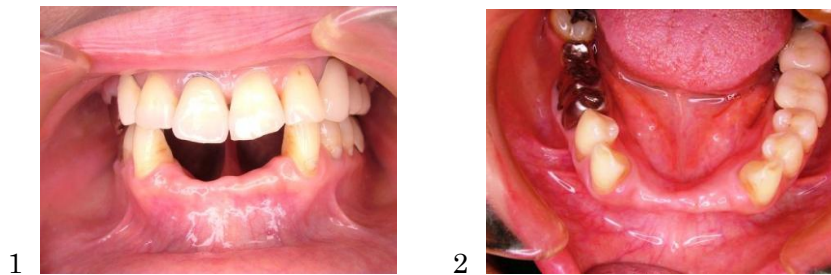


Image-1,-2: Preoperative state of the oral cavity. Vertical bone resorption and narrowing of the labiolingual width are featured.

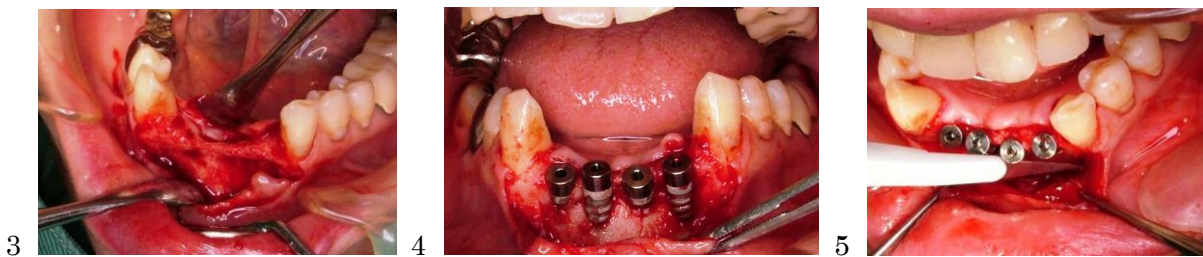


Image-3: Image of the oral cavity with the exposure of alveolar bone with mucoperiosteal flap formation.
 Image-4: Image of the oral cavity at the time of AQB two-piece implant insertion. The HA coating layer is completely exposed on the labial side, but was able to establish primary stability.
 Image-5: Release incision was added to the labial side mucoperiosteal flap.

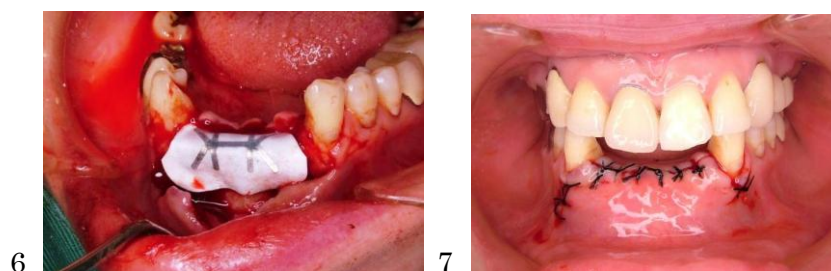


Image-6: Application of membrane to cover the HA coating completely.
 Image-7: Image of the oral cavity at the time of suture. Autogenous or artificial bone graft was not performed.

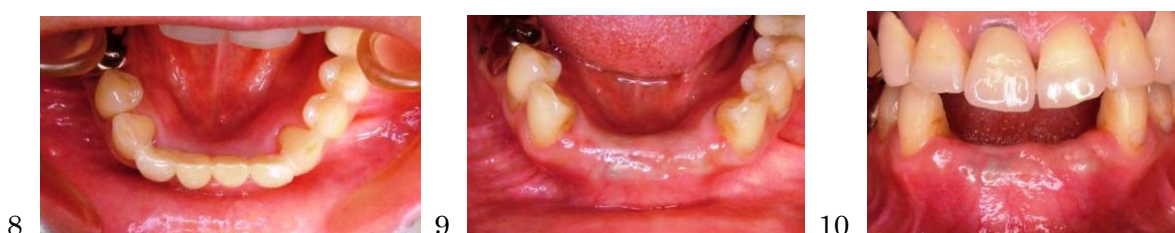

Image-8: Temporary crown was fitted for four months.

Image-9,-10: Image of the oral cavity after 4 months.

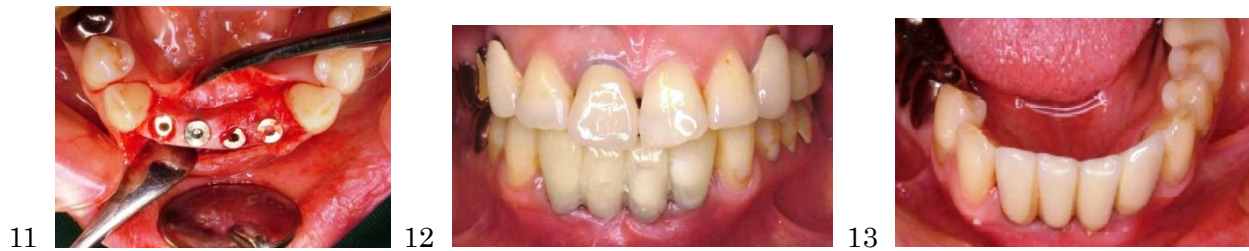

Image-11: Upon removal of the membrane, implant body was seen to be covered with neonatal bone.

Image-12: Abutment was mounted, and monitored the healing process for six months, protected by the placement of temporal crown. A satisfactory progress without any bone resorption was observed. Metal bonded crown was placed as the final prosthetics.

Image-13: Image of the oral cavity two years after the surgery. No gingival constrictions are evident.

11. A case where sinus-lift technique was applied with implantation

Professor of Dental Surgery, The Nippon Dental University Hospital

Masayori Shirakawa

General Manager of Department of Dentistry, Oral and Maxillofacial Surgery, Machida Municipal

Hospital

Takefumi Ogasawara

Instructor of Dental Surgery, The Nippon Dental University Hospital

Isao Hasegawa

When implanting to the region of maxillary molars, anatomically, the presence of maxillary sinus in itself can become the complicating factor of the surgical procedures. Especially in those cases where the alveolar bone resorption is significant or where the maxillary sinus has developed inferiorly. This can result in the short distances from the alveolar ridge to the maxillary sinus and the usual implantation procedures may be insufficient, and require concomitant use of vertical bone augmentation procedure.

Generally, in the region of the maxillary molars, a method to amplify the bone quantity on the base of the maxillary sinus with the addition of bone called the sinus lift procedure is employed. The method involves the detachment and lifting of the maxillary sinus mucous membrane.

Classification of the sinus-lift

This method can be largely divided into osteotome technique and lateral wall approach. The former method is generally known as the socket-lift technique and is the less invasive of the two types. Osteotome instrument is employed to grate the bone on the interior of the maxillary sinus. Contrarily, with the lateral approach, an osteotomy is performed on the lateral sinus wall to open a bone window which is then tacked in to allow access to the schneiderian membrane and to the sinus interior. The implantation can be done via a simultaneous approach or by a staged approach where the implant is only inserted after the healing of the bone augmentation with sinus lift procedure has been established.

Standards for choosing the sinus-lift

There are several factors that must be taken into consideration before implanting into the region of the maxillary molars with poor residual bone quantity. These include: the state of the bone, its quantity, and the position; but the ultimate decision is made in accordance with the height required for the lift. When it is less than 3 mm, socket-lift, but if more than 3 mm is required to be added, the use of lateral approach is recommended.

Advantages and disadvantages of sinus-lift

● Lateral approach

Advantages:

- Long length implant bodies can be installed.
- With sufficient visual clarity gained from detachment and lifting of the schneiderian membrane, issues such as membrane perforation can be readily treated.
- It can be applied to cases where the bone quantity and quality are insufficient achieve primary stability.

- The grafting region is easily accessible, enabling prosthetic treatment to be performed.

Disadvantages:

- Treatment outcome can vary significantly with the experiences and techniques of the practitioner.
- Damages or infections to the Schneiderian membrane carry the risks of complications and can lead to deterioration of physiological function.

- Osteotome technique

Advantage:

- Low level of invasion therefore is associated with reduced risk to the patient.

Disadvantages:

- Cannot be applied where bone quantity and quality are insufficient to achieve primary stability.
- The surgery is conducted “blind” therefore is difficult to address the complications such as the mucosal membrane perforations and bleeding.

Medical examination for sinus-lift procedure

Pre-surgical examination

The comprehensive examinations of the localized condition are made using panoramic radiograph, study model, Computed Tomography (CT). CT scan is particularly useful tool to determine accurately the condition of the state of the bone and schneiderian membrane of the maxillary sinus.

Complications: This involves any abnormalities of the maxillary sinus interior (inflammation, cyst, swellings). If a partition exists in the maxillary sinus interior, the detachment of the schneiderian membrane can be made complicated.

The sinus-lift procedure for AQB implant

1. Lateral wall approach (Figure 1)

- ① Inspect the maxillary sinus for the presence of pathological conditions (inflammation, cyst, swelling) using CT. Grasping the three-dimensional state of the maxillary sinus is required to acknowledge the position of the sinus floor from which to approach the lateral wall of the maxillary sinus, and the extent to which the sinus floor may be lifted.
- ② To expose the lateral wall of the maxillary sinus, the horizontal incision should be applied at the position that allows full coverage of the bone window with the mucoperiosteal flap, and the longitudinal incision should be drawn close to the point in which the gingiva from the jaw meets the buccal mucosa.
- ③ The lateral wall bone window of the maxillary sinus should be constructed using round bur or a diamond bur. The base of the window should not be extended to the point less than 3 mm from the sinus floor, and should be operated with application of physiological saline solution and while paying attention to avoid causing damages to the schneiderian membrane.
- ④ The schneiderian membrane should be carefully detached from the lower ridge of the window and the lateral ridge using the elevator designed specifically for this purpose. The elevator should be selected based on the state of the maxillary sinus and ensure that it is detached by moving the

elevator along the surface of the bone. This detached structure should be tucked into the maxillary sinus interior with the upper ridge of the window as the hinge. Secure a sufficient amount of space for it to be filled with the graft material. If the membrane has been completely detached without creating any perforations, the membrane movement in accordance with nasal respiration should be able to be observed.

- ⑤ Having determined the position of the implantation site, drill cautiously with consideration to the schneiderian membrane. Apply the bone graft ingredients to the sinus interior after drilling, and insert the fixture of the AQB two-piece implant. Re-apply the bone graft agent after the implantation, and cover the window opening with a resorbable membrane before closing the wound with suture.

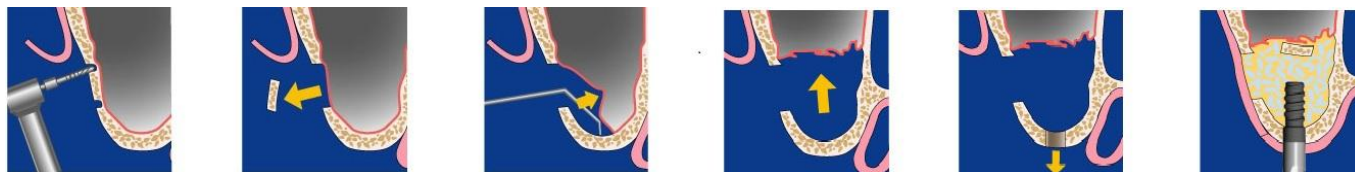


Fig. 1 Lateral wall approach

2. Osteotome technique (Fig. 2)

- ① Pre-surgical examination to determine the suitability of this technique. The applicable case is one that requires less than 3 mm of bone elevation.
- ② Insertion of AQB implant (4 mm in diameter). Drill a hole with the use of guided-drill (1.8 mm in diameter) leaving a minimum of 1 mm between the base of the implantation hole and the maxillary sinus floor.
- ③ Enlarge with 2.5 mm diameter drills then follow this by 3.5 mm diameter while ensuring that a distance of 1 mm is left without any penetration.
- ④ Malleting with osteotomes (2.8 mm and 3.5 mm diameter). Induce green stick fracture on the sinus floor. The malleting sound should change from a clear to dull upon fracturing the greenstick. Stop malleting once this occurs.
- ⑤ Fill the socket with the graft material and mallet again with the osteotome (3.5 mm diameter). The grafted bone also acts as the cushion for the implants at the time of malleting.
- ⑥ Implantation. If the implant cannot be fitted suitably, the placement hole can be modified with the use of end-mill reamer. Ensure at least 1 mm distance to be left from the maxillary sinus floor.

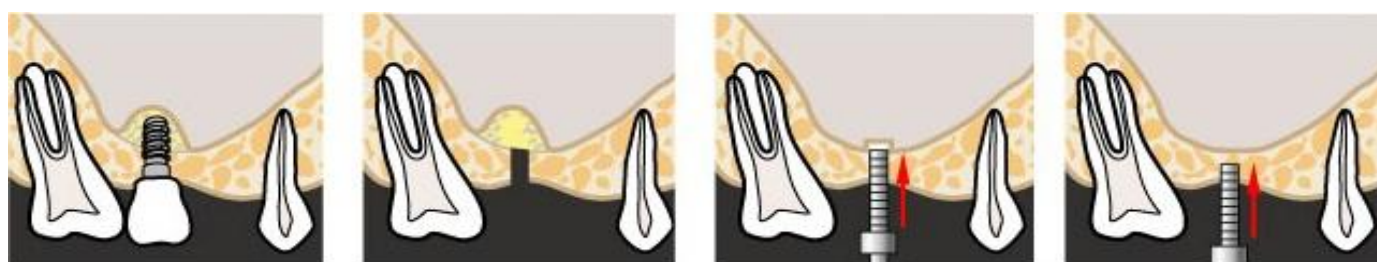


Fig 2. Osteotome technique

Accidental symptoms and complications

The common conditions that can arise during surgery include bleeding, injuries to the sinus membrane

and membrane perforation. Those arising post-operatively include sinusitis that can result from bacterial infections, and resorption of the graft materials.

Summary

Sinus lift procedure is a highly reliable method, where a successful outcome can be obtained by correctly application to the indicated conditions, and by mastering its surgical techniques. When performing the osteotome technique, great deal of precaution must be taken to avoid perforation of the membrane. If perforation does result, changing to lateral wall approach would be necessary.

A case study where sinus-lift method was adopted for the installation of two-piece implant

Patient: 53 year-old female

Chief complaint: Occlusal and masticatory disorder due to incompatibility of the denture.

Current symptoms: The width of the alveolar bone of the maxillary premolars had been sufficient, however, a buccal section of the maxillary molars showed a slight narrowing.

Radiograph analysis: The sufficient vertical height in the premolar regions were apparent from the panoramic radiograph but significantly reduced down to 2 - 3 mm in the molar regions. No thickening or cyst with the sinus membrane was seen.

Treatment

This case was presented with a lack of left premolar and molars (Image-1,-2), and, it was decided from the pre-surgical examination that implantation of AQB two-piece type would be conducted simultaneously with the sinus-lift method. Conduction anesthesia, containing vasoconstrictor (2% xylocaine (1/80000E), 7.2 ml) was induced. Having established sufficient level of anesthesia on the patient, a longitudinal incision was applied first to the left premolar region, and then along the alveolar crest at the position relative to the second molar, for clear detachment of the mucoperiosteal flap. This procedure was conducted with placing an elevator to the superior position. The bone window was first marked out on the anterior wall of the maxillary sinus, and was carefully curved out with a fissure bur (Image-3,-4). This position was hammered with bone chisel and mallet to create a point of entry, followed by the insertion of the membrane elevator to elevate the schneiderian membrane with great precaution to avoid its perforation. Although the sinus membrane was extremely thin, a sufficient level of elevation could be conducted (Image-5,-6). Three plantation holes were constructed on the alveolar crest, primarily using a round bur, then widened gradually with drills. Three AQB two-piece implants of type 4102 were inserted. Since the alveolar bone width was extremely thin, size SS abutment was fitted to avoid the implant body falling out.

The grafting material was collected by scraping the bone from the surroundings, and merged with β -tricalcium phosphate (β -TCP) to be added to the elevated space as well as those surrounding the implant body (Image-7). Absorbable membrane was placed to cover the bone window (Image-8) and was fixed. Release incision was applied to the mucous membrane to prevent any strain exerted, and was sutured with 5-0 nylon thread (Image-9). The procedure was completed having checked that the bleeding had stopped. The post-surgical radiograph confirmed the sinus floor to have been lifted to a reasonable level, with favorable implant orientation and the bone to have been sufficiently augmented (Image-10).

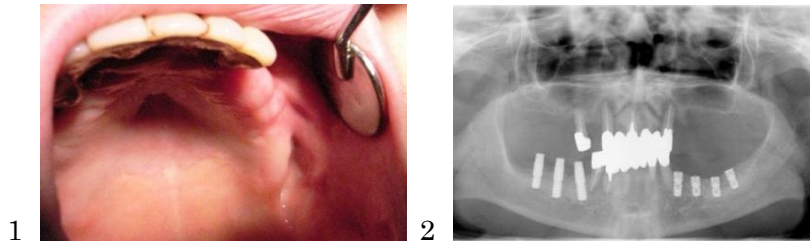


Image-1,-2: Photograph and panoramic radiograph of the oral cavity before surgery. The narrowing of the alveolar bone of the left maxillary molars is apparent.

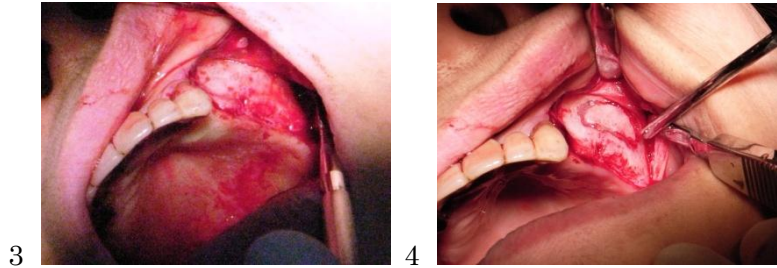


Image-3: Mucous membrane was detached to achieve sufficient visualization, and the bone was scored with fissure bur.

Image-4: The maxillary sinus lateral bone window was opened up.

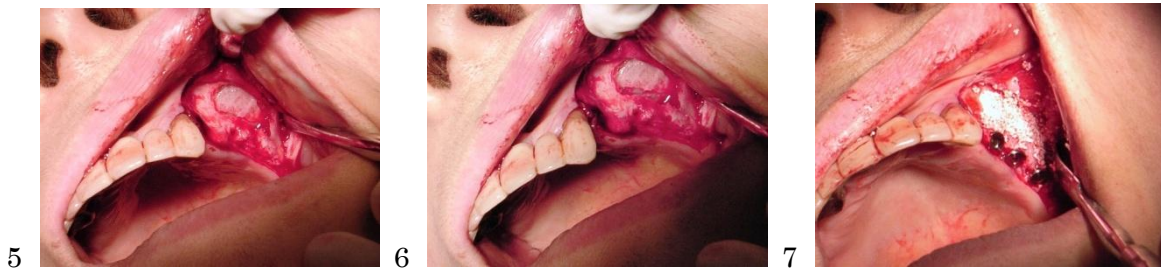

Image-5: Elevation of schneiderian membrane.

Image-6: Verifying the movement of the mucous membrane along with nasal respiration.

Image-7: Implant insertion, and filling the elevated space with the graft material, extracted autogenous bone mixed with β -TCP.

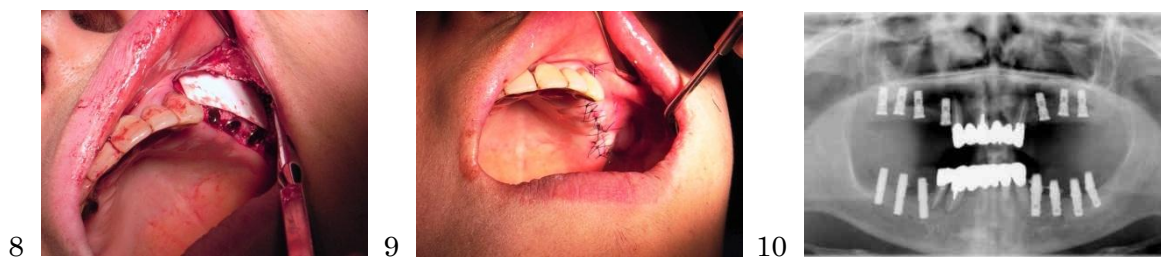

Image-8: Cover the window opening with absorbable membrane.

Image-9: Suture with nylon thread

Image-10: Post-surgical panoramic radiograph. The opaqueness of the surrounding bone can be observed in the radiograph due to the presence of β -TCP .

12. A case where the occlusion was reconstructed with implantation, facilitated with bone augmentation and elevation of bilateral maxillary sinus floor to maxilla edentulous patient.

Oral-Maxillofacial Surgery, Dentistry and Orthodontics,
The University of Tokyo Hospital

Nobuko Hayashi

Instructor of Oral-Maxillofacial Surgery, Dentistry and Orthodontics,
The University of Tokyo Hospital

Hideto Saijyo

There are cases whereby implantation into the region of maxillary molars is complicated due to insufficient bone quantity. Such issues can be overcome by conducting sinus-lift to detach and elevate the maxillary sinus floor with grafting autogenous bone.

In contrast to the socket lift technique that necessitates the alveolar bone, the lateral wall approach can be applied even to those cases where the bone quantity is insufficient to achieve primary stability. The teeth loss in the anterior region is often associated with alveolar bone narrowing particularly on the labial side due to the pressure exerted from the lips.

This example presented with the narrowing of the anterior alveolar crest. The occlusion was successfully reestablished in this case by conducting bone augmentation procedure to the anterior region and sinus lift to both the sinuses to increase the length to the maxillary sinus in the molar region on both of the sides that were shown to be only few millimeters.

Patient: 50 year-old female

Chief complaint: Inability to chew

Medical history: Periodontal disease affected teeth had been extracted at the previous clinic. Several AQB two-piece type implants were inserted to this edentulous jaw. However due to infection, they are required to be removed.

Current symptoms: The jaw is undergoing progressive bone resorption, and has been placed with two implants (by a nearby clinic). In addition, a temporary denture had been placed but its occlusal height was low, therefore had been resulting in an incompatible occlusion. The panoramic radiograph at the first medical examination confirmed the lack of bone quantity (Image-1).

Treatment plan: CT scan featured whole of the alveolar bone to be resorbed indicating difficulty in its implantation with the standard procedure. The following procedures were planned for this patient as she requested the placement of crown as the superstructure.

- ① Autogenous iliac bone graft to the left maxillary sinus floor elevation and osteogenesis of anterior alveolar crest.
- ② Recovery of occlusal height with fabrication of temporary denture.
- ③ Implantation of two-piece types from the left molar to the anterior.
- ④ Implantation immediately following maxillary sinus floor elevation procedure.
- ⑤ Secondary surgery on the right hand side
- ⑥ Placement of provisional restoration.
- ⑦ Mounting of porcelain bonded metal crown.

Left maxillary sinus floor elevation with autogenous iliac bone graft, and osteogenesis of the anterior alveolar crest.

Left maxillary sinus floor elevation (right autogenous iliac bone graft) was conducted under general anesthesia. The alveolar crest had been prominently resorbed and showed significant narrowing. The surrounding tissues of the implant that had been inserted previously had become replaced with infected granulation tissues.

The bone window was created on the lateral wall of the maxillary sinus with taking opposing teeth into account (Image-2).

The bone on the sinus wall was scored using diamond round bur (3 mm diameter), identified the schneiderian membrane and was detached and elevated with sinus-lift elevator (Image-3). Once sufficient elevation of the sinus membrane was confirmed, the space was grafted with autogenous iliac bone that had been extracted earlier. In order to secure a sufficient alveolar bone width on the buccal side, bone augmentation procedure using cortical bone graft was applied concomitantly.

The cortical bone block was screwed tightly to the anterior teeth region (Image-4), and the implant at No. 7 position was removed due to its instability and development of granulation tissues. Meanwhile, the implant on the opposite side was left unremoved since it was verified to have established osseointegration. The mucoperiosteal flap was closed after the application of sufficient release incision.

Post surgical radiograph (Image-5) is featured. Three months after the left maxillary sinus floor elevation procedure, screw removal and implant installation to the left of the anterior region were conducted under local anesthesia. The adhesion of the bone graft was found to be in favorable condition (Image-6).

Six AQB two-piece implants, all of which were 4102-type, were inserted (Image-7). The primary stability was able to be achieved.

On close inspection of the previously implanted structure, it was found that the coating to be partially exposed therefore was decided to be removed at the same time as conducting the sinus-lift on the right. Three months after the first batch of implantation, the sinus-lift procedure (right autogenous iliac bone graft), implantation to the same area (three AQB two-piece implants), as well as the secondary surgery from the left to the anterior were conducted.

The sinus-lift method was performed following the standard protocol, such that the bone window was sculpted on the lateral wall of the sinus. Upon confirming that sinus floor had been sufficiently elevated, implant cavity was constructed in the alveolar bone. The depth and the orientation of the cavities were verified with the use of alarm gauge (Image-8). The cancellous bone extracted from the ileum was compounded into the space; then the implant was inserted. Roughly 1 mm of the implant coating became exposed on the labial side therefore the cancellous bone was applied additionally (Image-9). Healing abutment (SS) was placed to prevent the fixture subsiding into the sinus for it to be left for three months before conducting the secondary surgery.

The panoramic radiograph taken after the operation confirmed absence of any bone resorption, as well as osseointegration to have been achieved.

The masticatory function of the patient has shown a significant improvement since the superstructure was placed a year ago, and is pleased with the esthetic outcome.

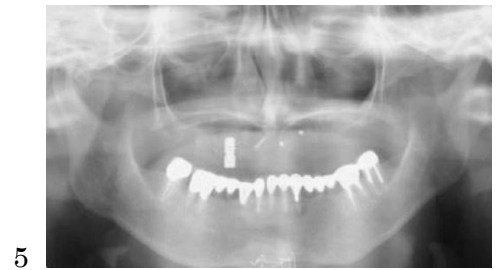
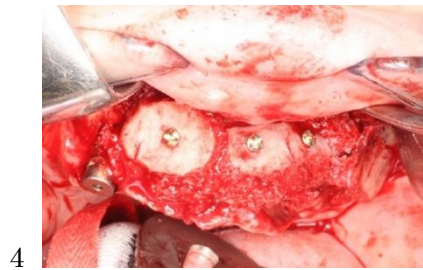
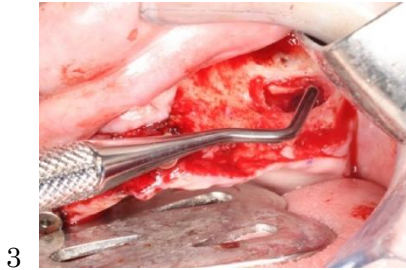
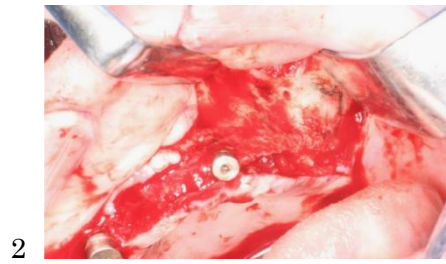
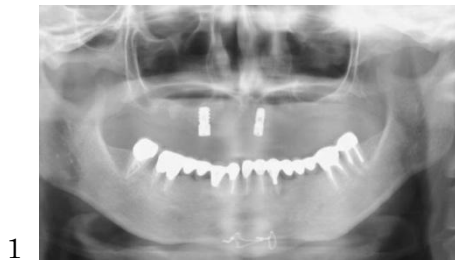

Image-1: Panoramic radiograph at the first medical examination

Image-2,-3,-4: Images featuring the sinus-lift procedure. 2. The sculpting of the bone window on the lateral wall of the maxillary sinus. It was set with taking into consideration the relationship with the opposing teeth. 3. Sufficient elevation of the sinus floor. 4. Cortical bone was grafted on the buccal side, and was screwed on and was left to set.

Image-5: Post-surgical panoramic radiograph.

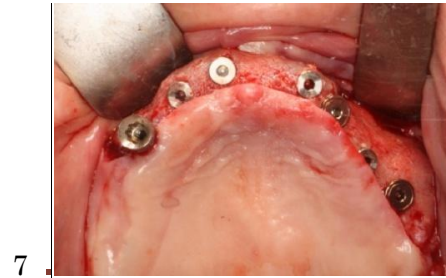
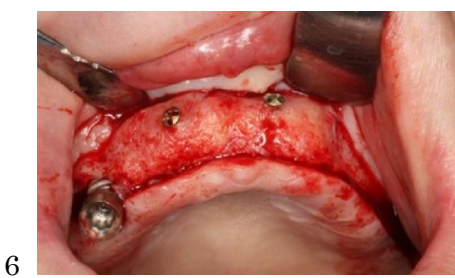
Image-6,-7: Image during the insertion of implants to the left anterior teeth. 6) The grafted bone appeared to be in good condition. 7) Six AQB two-piece implants were inserted.

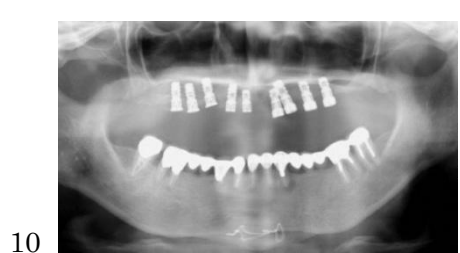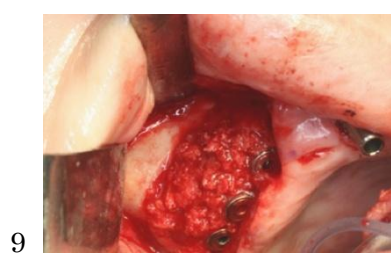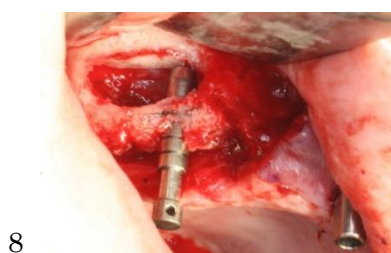


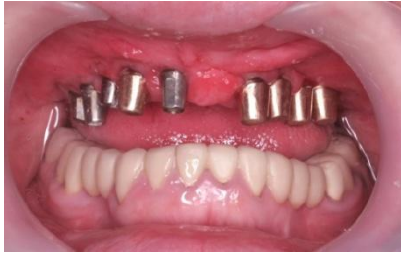Image-8,9: Images featuring the sinus-lift procedure to the right. 8) Implant cavities were constructed and its depth and its orientations were verified using alarm gauge. 9) The state after the bone graft, having inserted the implants.

Image-10: Panoramic radiograph taken after implant insertion.

11



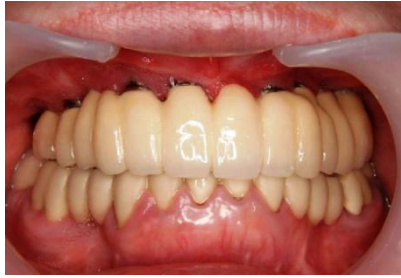
12



Image-11: Implant set with inner crowns.

Image-12: Inner crowns

13



14

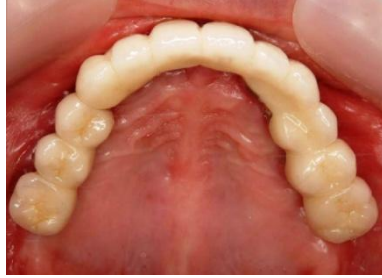

Image-13,-14: Image of the oral cavity fitted with final prosthetics.

13. A case where bone regeneration technique was conducted by the application of sinus-lift without autogenous or artificial bone graft.

Head of Oral and Maxillofacial Surgery, Tokushukai Group
Assistant Director of Tokyo West Tokushukai Hospital
Tsuguo Sano

The implantations to the bones of the maxillary sinus which have been severely reduced are usually facilitated with sinus-lift, followed by bone augmentation procedures. There have been a significant number of methods taken establish the location from which to extract the bone, to find a suitable extraction site that is not predisposed with infection, and one that would provide solid bone formation. There have been case seven with the vertical bone augmentation procedures performed implantation was not compatible due its lack of tenacity.

AQB implant has been noted to have osteoconductivity. Therefore in utilizing this property, it was possible to conduct socket-lift with one-piece implant instead of the sinus-lift procedure. The introduction of T-type implant into the market that was able to reduce the risk of implant body subsidence into the maxillary sinus acted as an added advantage for the use in similar procedures. Furthermore, the primary stability could be established by the application of composite resin to the implant abutment thus enabling the use of AQB one-piece implants to these cases without involving the sinus-lift procedure.

A case is presented, where implantation was conducted to the alveolar bone (3 mm) that had been treated with socket-lift procedure.

Patient: 47 year-old female

First admission: March 2007

Chief complaint: Requested implant treatment

Treatment plan: Conduct elevation of the maxillary sinus membrane with socket-lift method, and augment the bone in a way that no strain is exerted on the implant body for at least two months following its installation. Once confirming augmentation of the bone with simple X-ray, place temporary crown for light loading, and then fabricate the final prosthetic structure.

Panoramic radiograph of the right maxilla right before the implant insertion is shown (Image-1). Incision into the gingivae and elevation of the flap were conducted following the standard procedures. The bone was then pierced through with spiral drill, being cautious, not to damage the sinus membrane. Upon confirming that no damages have been made to the membrane under clear vision, detach the membrane then lift the membrane gradually with End-mill reamer. In the absence of abnormal symptoms, two, T-type, 5MM implants were installed. Two months after the surgery, regeneration of the bone was

confirmed with panoramic radiograph (Image-2). The final prosthetic structures were fabricated after light loading for a month with the placement of temporary crowns. The patient was highly pleased with the outcome especially since the implantation had been refused by a number of other clinics.

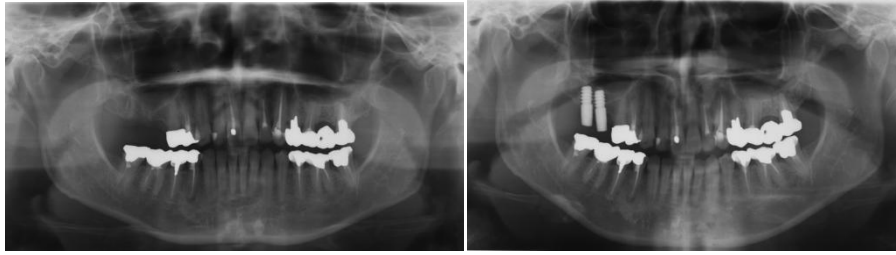


Image-1 Preoperative
panoramic radiography

Image-2 Panoramic radiography
2 months after implantation

14. A case where the socket-lift procedure was adopted for lack of vertical height of the bone on the maxilla.

Oral-Maxillofacial Surgery, Dentistry and Orthodontics,
The University of Tokyo Hospital

Nobuko Hayashi

Instructor of Oral-Maxillofacial Surgery, Dentistry and Orthodontics,
The University of Tokyo Hospital

Hideto Saijyo

When performing implant treatment to the maxilla for which the vertical height of the remnant alveolar bone is insufficient, a maxillary sinus floor elevation becomes necessary. There are two main methods for this: the sinus-lift with the lateral wall approach, and socket-lift that applies osteotome technique. The socket-lift has been applied widely in clinical settings due to its less invasive nature as a method for maxillary sinus floor elevation. A case is presented where the socket-lift method was applied for the alveolar bone that was presented with vertical height shortage.

Patient: 51 year-old female

Chief complaint: Masticatory difficulty from the lack of left molars.

Past medical history: Nothing to note

Current medical history: No. 2 and 3 teeth were extracted 15 years ago, and No. 4 tooth, removed three years ago. Cantilever bridge was mounted at the time, as it was deemed impossible to install implants after the teeth extraction.

Current symptoms: No. 2 to 4 teeth were missing, No. 5 was placed with cantilever bridge pontic without the placement of partial dentures. There appeared to be no issues with the level of oral cavity hygiene. The conservative therapy of No. 9 and 10 teeth had become difficult due to the damages done to the bridge. Instead, it was planned that transitional partial dentures would be fabricated to restore the original occlusion after their extraction. Concurrent elevation of the sinus floor with the implant installation may be considered depending on its condition after wound had healed.

Systemic condition: Nothing to note

On initial inspection, significant bone resorption at the positions No. 5 and 6 was confirmed, with 2 to 3 degrees of mobility, therefore were decided to be removed (Image-1). No. 5 and 6 were removed, and was replaced with fabricated partial dentures. The state of bone regeneration of the tooth extraction site was confirmed after a period of half a year, at which time implant treatment was carried out. The case presented with a relatively poor vertical height at the maxillary molar region, therefore it was reassessed with the use of CT scan once sufficient a degree of osteogenesis of the extraction socket bone had been confirmed. The simulation of the treatment course was carried out with the application of CT data to SimPlant® (Image-2-a to e). This confirmed the distance from the alveolar ridge to the base of the sinus to be a mere 3 mm, confirming the insufficient quantity of the bone. The labiolingual width at the thinnest section was 6 mm therefore the socket-lift method with the use of osteotome was applied here. There was a risk of the implant body subsiding into the sinus interior, therefore considering this and its requirement for stress and for safety, AQB T-type was selected.

T-type was also selected for the positions No. 5 and 6, to secure adequate strength of the implant body to withstand the occlusal pressure. As initially planned at the primary consultation stage, implants of type, T3MM to No. 6, T4MM to No. 5, and T46S to No. 3 and 4 (with addition of 4 mm with socket-lift to 3 mm original height) were installed, completing the procedure (Image-3,-4). Satisfactory primary stability could be obtained, without much exposure of HA coating, therefore no further measures such as fixing or linkages of the implant bodies were required (Image-5-a to c). The porcelain bonded-metal crown (connected crown) was mounted three months after implant installation. Vast improvements with regards to the masticatory function as well as estheticism could be achieved (Image-6-a to c).

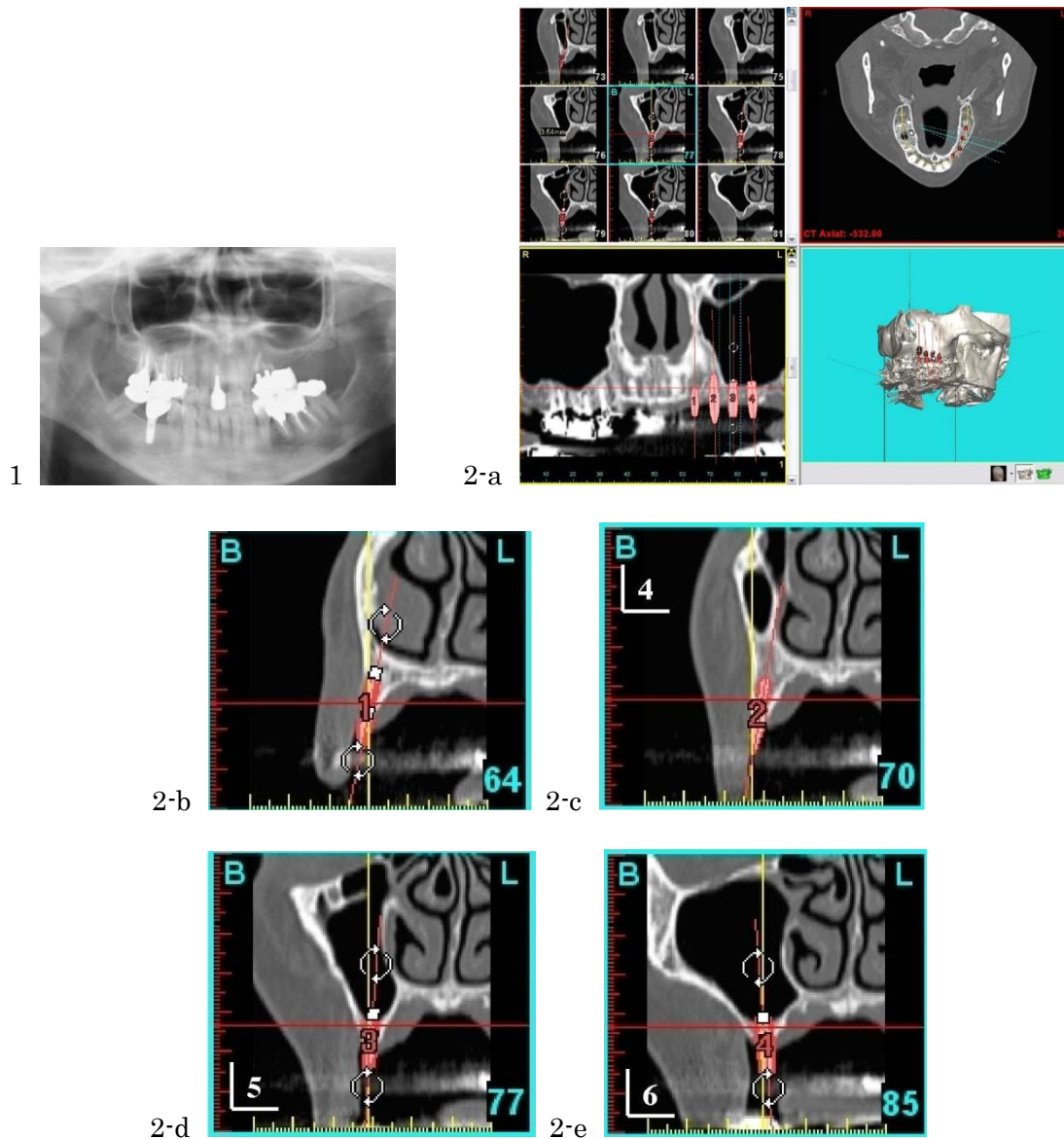


Image-1: Panoramic radiograph at the primary medical examination.

Image-2-a,b,c,d,e: Simulation images with SimPlant® (full picture).

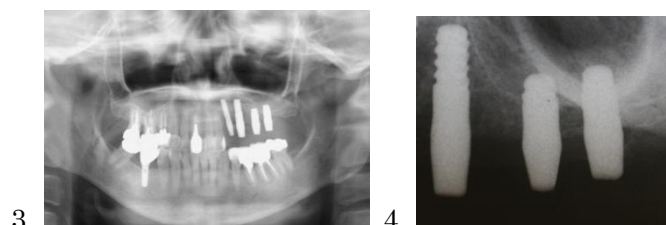


Image-3: Post-surgical panoramic radiograph.

Image-4: The cortical bone of the maxillary sinus floor has been lifted in a tent-like manner (red arrow).

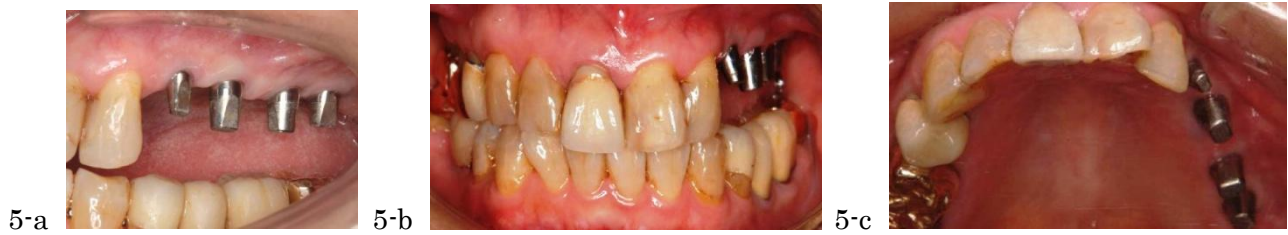

Image-5-a,b,c: Image of the oral cavity interior before the placement of the final prosthesis.

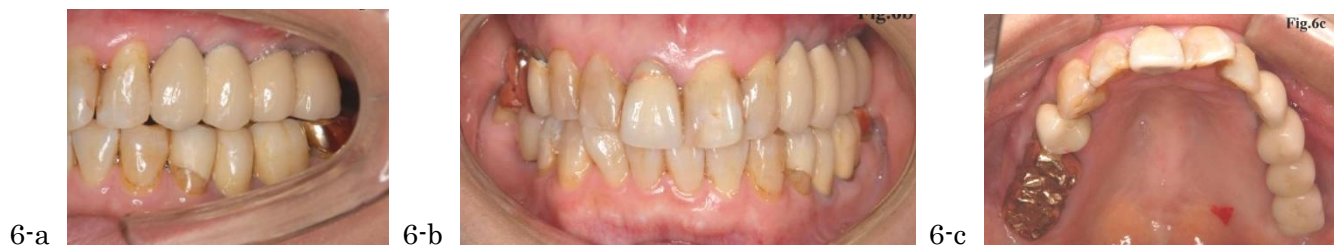

Image-6-a,b,c: Image of the oral cavity interior after the porcelain bonded-metal crown has been mounted.

15. Socket-lift method with drilling through the bone.

Director of Kinebuchi Dental Clinic

Takao Kinebuchi

Maxillary sinus floor elevation

As mentioned in the previous cases, the main techniques for raising the sinus floor up to now have included the lateral wall approach where the bone window is formed on the wall of the sinus (sinus-lift), or the socket-lift method where the cortical bone on the sinus base is hammered from the implant cavity constructed with the osteotome to lift this structure. With the introduction of novel tools such as those included in the Sinus Lifting Technique® developed by Dr Cosci, or the alarm gauge for 3 mm and 4 mm presented by the author at the 6th IAI academic conference, the techniques have shifted towards the use of socket-lift with drills. The alarm gauges for 3 mm and 4 mm are used primarily to detach and lift the sinus membrane instead of using the elevator, while piercing through the cortical bone of the sinus base with 5 mm spiral drill. This is followed by the plantation with bicortical anchorage with the intension to strengthen its primary stability (Fig.1- ①②).

Socket-lift method using drills for cavity construction

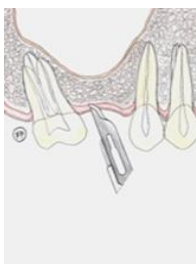
Course of development of this method: In the case of socket-lift technique using osteotome to undergo process of “alveolar approach”, the greenstick is fractured by osteotome. There is a risk of the cortical bone of the sinus base fracturing in a disorderly fashion, in which case, the primary stability can be worsened. The primary stability is particularly important for installation of the one-piece type on contrary to the two-piece type. Therefore we investigated the means of using the drill to pierce through the cortical bone of the sinus floor, after the initial drilling to form a small orifice to gradually detach and lift the sinus membrane from this small opening. This study was initially presented at the 6th IAI conferences (August 2003), and have continued to investigate this technique in terms of procedures. This technique has become an essential tool to expand the scope of the indications for which implants can be applied to, and to show this, there were a large number of requests from those who had attended the AQB basic course to also hold the advanced course. To meet this demand, “AQB advanced course” was started as a training course from February 2004. This has since been implemented as a practical course, the “simple implant” with the socket-lift model developed by the Nissin dental products Inc. as a part of the CDE course of Dental Alumni Association of Tokyo Medical and Dental University, as of September 2005. In December 2008, the introduction of this method, alongside its clinical evaluation of period of ten years was presented at the Japanese Academy of MaxilloFacial Implants. This technique has been mentioned in the AQB Newspaper but since the details were omitted, I will introduce the technique here.

Indications and methods

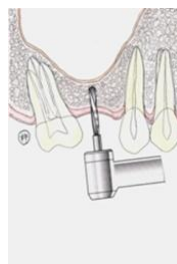
We present here the cases that were installed with sinus-lift technique in which the holes were constructed with drills, out of all the cases that have been installed with AQB implants (501 patients, 1598 implants) in the period of ten years, since December 1998 to October 2008, (113 patients, 180 implants). The technique that we have been investigating into, fundamentally applies 5 mm diameter-implants to the molar region, so here the steps following the detachment and elevation of the alveolar ridge membrane are described below.

Socket-lift method piercing with drills

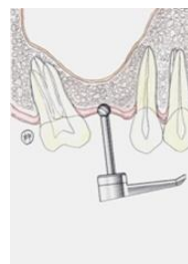
- ① Determining the location with the round bur
- ② Mark a hole with a guide drill
- ③ Drill to the point before the cortical bone of the sinus base with the spiral drills of increasing diameters, from 3 mm (ϕ 2.5 mm), 4 mm (ϕ 3.5 mm), 5 mm (ϕ 4.5 mm).
- ④ Determine the gradual expansion of the small opening in the cortical bone on the sinus floor with the tip of the 5 mm spiral drill with the use of tools such as a depth gauge.
- ⑤ Three mm alarm gauge can be fitted through the bone perforation upon reaching 2.8 mm in diameter, to sense the sinus floor mucosa. This should then be held by the hand in an angle for slight detachment and lifting of the membrane in the order of buccal, palatal, distal and mesial directions.
- ⑥ Four mm alarm gauge can be fitted through, upon reaching 3.8 mm diameter, with continuous drilling with 5 mm spiral drill. It can also be used to further detach and lift the membrane.
- ⑦ Pierce through the cortical bone of the sinus floor with the 5 mm spiral drill with extreme caution. (Here, the over-run of the drill should be limited to within 2 mm after the cortical bone has been pierced through, to prevent any perforation of the membrane).
- ⑧ Pierce through the cortical bone with end-mill reamer (ϕ 4.75 mm)
- ⑨ Confirm that the elevation has been performed to a sufficient depth with the 5 mm alarm gauge (ϕ 4.8 mm)
- ⑩ Complete the hole with the finishing reamer (ϕ 4.9 mm) if necessary.
- ⑪ Confirm the absence of any perforations to the sinus floor mucosa with the use of depth gauge.
- ⑫ Trim the mucosal membrane with a circular knife.
- ⑬ Install implant body with a fixer and a free wrench (if any chipped bone was collected during the construction of the cavity, add into the implant cavity before implant insertion).
- ⑭ Closing the mucoperiosteal flap.



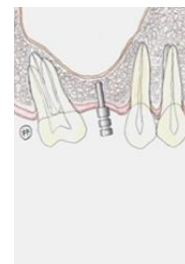Incision and detachment



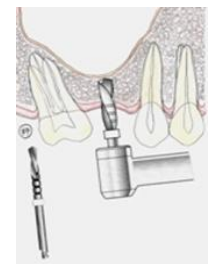
Round bur



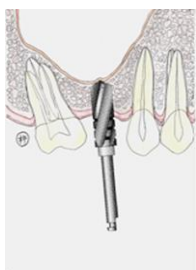Guide Drill



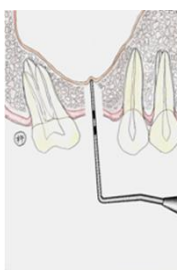
Direction Checker



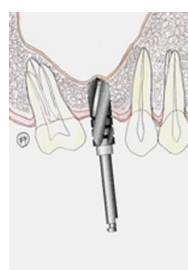
Spiral drill for 3 and 4 mm



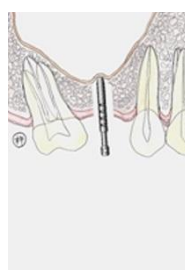
Drill 1.5 mm diameter hole through the cortical bone with a 5 mm drill



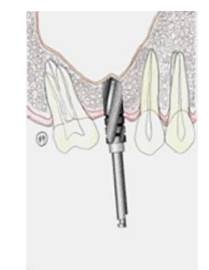
Inspect sinus membrane with depth gauge



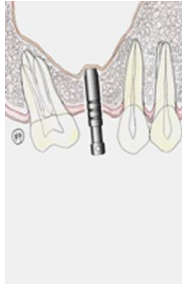
Drill 2.8 mm diameter hole through the cortical bone with a 5 mm drill



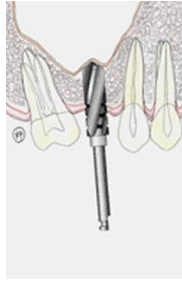
Elevate the sinus membrane with the 3 mm trial guide



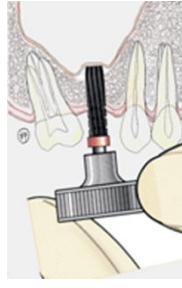
Drill 3.8 mm diameter hole through the cortical bone with a 5 mm drill



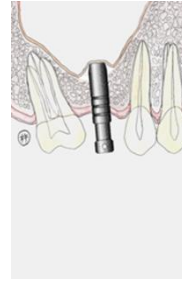
Elevate the sinus membrane with the 4 mm trial guide



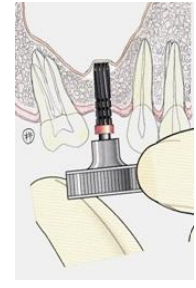Break through the cortical bone with a 5 mm drill



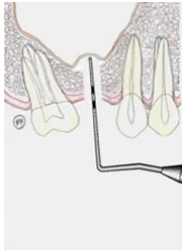
Break through the cortical bone with end-mill reamer



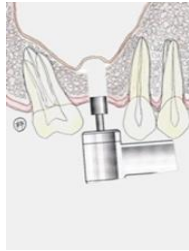Elevate the sinus membrane with the 5 mm trial guide to the point required



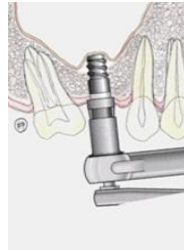Reamer to finish



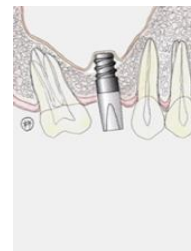
Check for sinus membrane perforations with a depth gauge



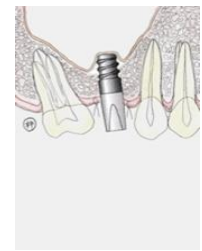
Trim gingiva with a circular knife



Implant with a wrench



Insert AQB implant



Closing the mucoperiosteal flap

Note of caution:

- ① If sufficient clearance cannot be achieved, the abutment should be corrected at its interdigation. (If the primary stability cannot be established, temporarily fix with other implants fitted at the same time or with the neighboring natural tooth that show sufficient degree of stability).
- ② Explanations to the patients (e.g. the risk of the implant body subsidence into the maxillary sinus if chewed with the implanted region, do not blow your nose harshly for about a week).

Additionally, the measures that would be taken in the case of membrane perforation should be given to the patient before the operation. The implant cavity will be constructed to the point just before implantation, but the actual insertion of the implant body will be delayed for one to one and a half months, during which time, the mucoperiosteal flap will be closed to allow the healing process.

At the time of subsequent implantation, the best means is to first detach and incise the flap, enlarge the implant cavity to its mid-section with the end-mill reamer, as mentioned in step ⑧, and then detach and lift the sinus floor mucosa along with the connective tissues on the base of the implant cavity with the alarm gauge as mentioned in ⑨. This method often enables the implant installation to be conducted with the socket-lift method without causing any perforations in the sinus base mucosa.

Results

Out of the 180 implants installed, 144 showed satisfactory progress without bone resorption; 30 that show a bowl shaped bone resorption that are not progressive, and are currently stable; 6 were removed (3 due to bone resorption due to external forces, 2 due to inability to achieve primary stability therefore were not osseointegrated, 1 that was infected when undergoing chemotherapy). These results have given rise to a survival rate of 96.7%. Other cases include those that resulted in the membrane perforations in the

primary surgery, 15 implants that were inserted concomitantly with socket-lift, and 2 with sinus-lift. In addition, there was a case whereby the sinus membrane was incredibly fragile that it resulted in re-perforation at the second installation attempt. As the implant was not be possible, it has not been counted.

AQB size that are used in socket lift

- Use of 4 mm diameter AQB is unavoidable for oblique socket lift at premolar, however 5 diameter should be used for full socket lift and socket lift at molar.
- A standard for AQB size

Size of AQB	Distance until maxillary sinus floor	Clearance until opposing tooth	Thickens of alveolar mucosa
5MM - 5 ML	7 - 9 mm	Big	Thick
5SM - 5 MM	5 - 7 mm	Big	Thick
5SS - 5 MS	5 - 7 mm	Small	Thin
#568 - 5 SS	3 - 5 mm	Small	Thin

(Reference)

The AQB sizes used to pierced through the bone in socket lift procedure

Discussions and conclusion

The socket-lift method with respect to the lateral wall approach is a surgical procedure that is less invasive in comparison to the sinus-lift method. With respect to the AQB implants that have been coated with highly pure recrystallized HA, there is no additional requirement for autogenous or bone filling agents, but the chronological observations have noted the tip of the implant body to push through the sinus floor mucosa and result in the formation of the neonatal bones in the shape of a pyramid. There have been many reports of socket-lift methods, but the technique we have introduced here can be conducted with only the basic tool set therefore can be said to be a more practical one.

A case example where the drill was used to pierce through the bone for a socket-lift method

A patient had been undergoing regular treatment at the general clinic for ten years period. The region of maxillary molars that had been missing was replaced with a plate denture. The AQB implants had been planted and prosthetics mounted at our clinic, every time the maxillary anterior teeth and premolars had become lost (No. 7, 09.06.99; No. 8 02.19.02; No. 12 04.07.03). The maxillary sinus of this patient was large, and the bone quantity to the base of the maxillary sinus, in the region of No. 2 to 4 and No. 13 to 15 were believed to be impossible for implants to be installed therefore had been placed with plate dentures. However it was thought that by implementing the sinus lift procedure, implantation would be possible. The occlusion of the right molar region could be restored by implanting to No. 13 to 15 positions (07.07.2003) with the lateral wall approach, and the placement with a bridge. As the height of the bone in

the region of the left maxillary molars had become even less, we had half given up on implanting in this region. However, installation to No. 4 and then to No. 2, in this order, was made possible by applying time lag in the implantation (refer to Part 2, Chapter 4 'Treatment plan' for further details), with the use of socket-lift. The socket-lift method at these two positions enabled the detachment and elevation of the maxillary sinus mucosa with the socket-lift procedure, and this process is presented here.

Patient: 38 year-old female

First admission: August 1998

Chief complaint: Request for implant installation to No. 7 and No. 12 that were damaged and extracted.

Primary treatment plan: Initial general treatment, placement of the plate denture, and implantation once the bone was stabilized.

Secondary treatment plan: Implantation to No. 13 to 15 positions with sinus-lift, and bridge placement

Tertiary treatment plan: Implantation to No. 2 to 4 positions with socket-lift and bridge placement.

Current condition and the treatment progress

Implant, 4LM, was installed into the jaw on September 6th 1999, followed by metal bonded crown placement on December 27th 1999. No. 13 that had been acting as an anchor had been affected by bone resorption, and No. 8 due to root fracture were extracted on March 24th 2000 and October 16th 2001, respectively. On February 19th 2002, 4LM was placed at No. 8 position, and metal bonded crown was placed on the September 6th 2002.

Implant, 4SM, to No. 12 was installed on April 7th 2003, followed by installation of 566, 568 to the positions No. 13 to 15 with sinus-lift. And the secondary surgery was completed on January 27th 2004 with the mounting of the bridge and metal bonded crown to No. 12.

The tertiary surgery was commenced on the January 9th 2007 with the installation of 5SS type implant to No. 6 position, with the socket-lift method. The dental radiograph, taken straight after the implantation, clearly shows blood to be retained in the space under the detached and elevated schneiderian membrane. The composite resin crown was mounted three months later, and prepared for the installation at position No. 2 where the bone was particularly narrow. July 24th 2007, 568 was installed to position No. 2 with socket-lift procedure. The height of the bone to the floor of the maxillary sinus was more than expected which appeared to be owing to a wide detachment and elevation of the sinus membrane at the time of implantation to position No. 6 and that was further lifted up with the sinus-lift method. Fortunately, the primary stability of implant to No. 2 was deemed sufficient, therefore additional connection to be made immediately following the implantation was not necessary. Instead, the regeneration of the bone was accelerated by applying a weak occlusal force by connecting the resin crown of No. 4 with self-curing resin to resin crown with the pontic placed on No. 6 and 7, two months later. The final bridge prosthesis was placed on December 17th 2007, which is 11 months after the implantation to No. 4 position, and 5 months after installation to No. 2. The state of the bone appears stable in both the right regions that underwent sinus-lift procedure, and left that underwent socket-lift procedure.

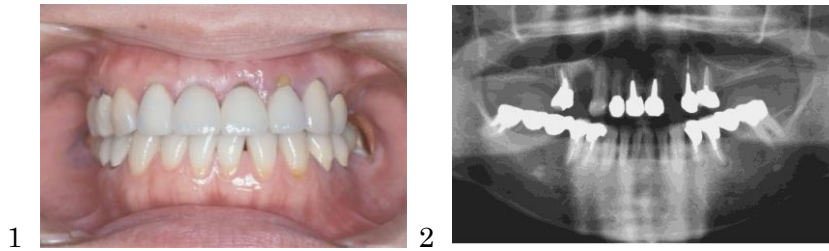


Image-1: Image at the time of first consultation (08.07.98).

Image-2: Panoramic radiograph taken after the extraction of No. 7 and 12 teeth, due to tooth root breakage.

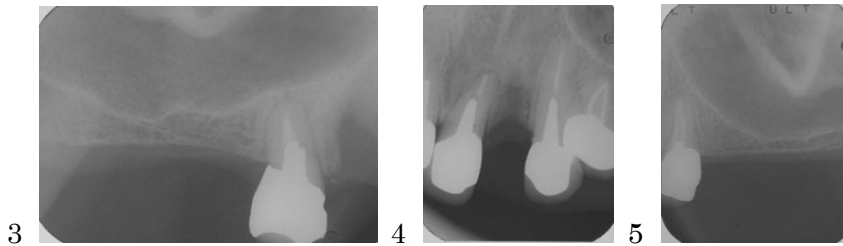

Image-3,-4,-5: Dental radiographs featuring the state four months since No. 7 and 12 extractions (12.11.1998). The alveolar bone height at the positions No. 2-4 and No. 13 -15 are low.

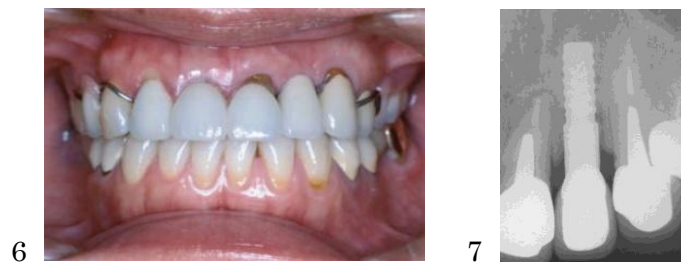

Image-6,-7: Image of the oral cavity and radiograph featuring the 4LM implanted to position No. 7 after the jaw bone had stabilized (06.09.1999), placement of the metal bonded crown (12.27. 1999).

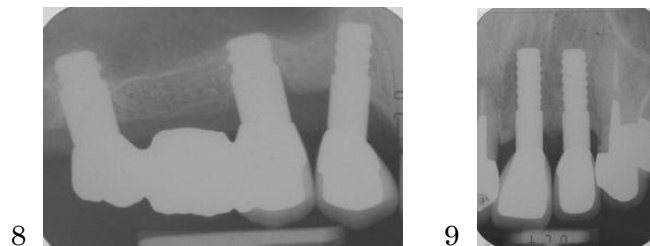


Image-8,-9: Dental radiograph at the end of the secondary surgery (06.08.2004). No. 13 that had been acting as an anchor was lost due to external bone resorption (03.24.2000) No. 8 tooth was extracted due to its root fracture (10.16.2001), therefore it was installed with a 4LM implant (02.19.2002), followed by a placement of the metal bonded crown at this position (09.06.2002). 4SM implant was installed at position No. 12 (04.07.2003), followed by 566 and 568 to No. 13 and 15 positions (07.07.2003). The metal bonded crowns were mounted onto No. 13 and 15, as well as to No. 12 position (01.27.2004).

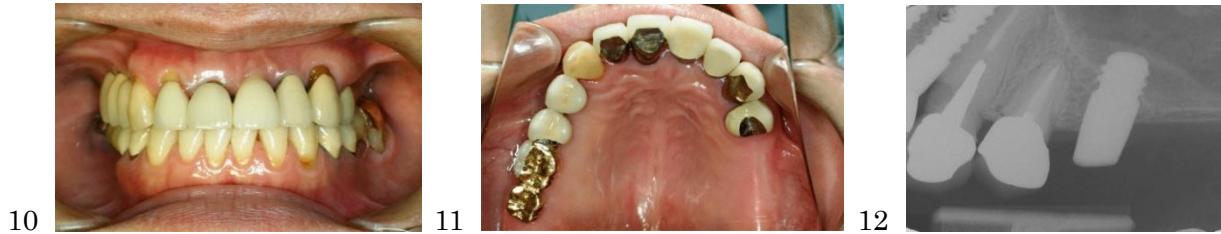

Image-10, 11: Images showing the state at the end of the secondary surgery (06.08.2004).

Image-12: The dental radiograph taken at the time of tertiary surgery. The 5SS implant was installed to No. 12 position with socket-lift procedure. The image displays the state of the blood pooling in the space under the mucosa that has been detached and elevated. Resin crown was placed three months later, and prepared for the case where the primary stability of AQB implant was insufficient at the position No. 2 where the bone was particularly narrow.

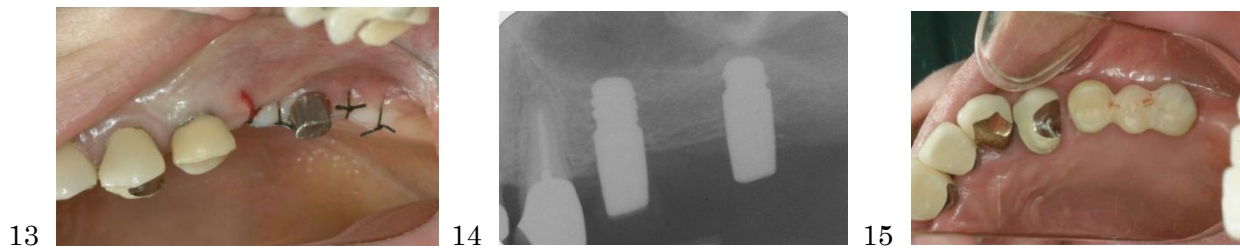


Image-13,-14: The image of the oral cavity and dental X-ray after the 568 implant was installed to the position No. 2 with socket-lift procedure. Unexpectedly, it was found that the sinus floor mucosa had been detached and lifted more widely, at the time of implant installation to position No. 4, along with the growth of the height of the bone, and the socket-lift had caused the region further along to also be detached and lifted.

Image-15: The image features the state three months after the implantation to No. 2 position. Fortunately, a sufficient primary stability of No. 2 implant was able to be achieved. Although there was no need for an aid to stabilize the implant body straight after its installation, however, it was mounted with a pontic attached resin crown to No. 2 and 3 positions and then connected to an immediate loading resin to be placed on the implant at No.4 position resulting in a bridge placement. A weak occlusal force was exerted to accelerate neonatal bone development (10.23.2007).

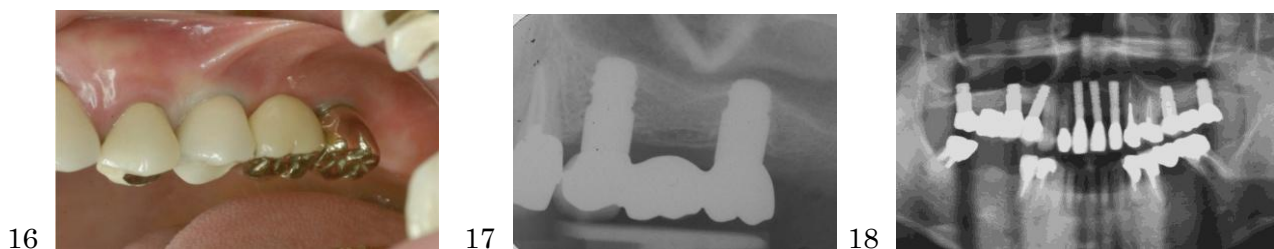

Image-16,-17: Image of the oral cavity as well as the radiograph featuring the state after the final bridge superstructure was mounted. The bridge was placed 11 months after the implant installation to No. 4 position, and 5 months after No. 2 position (12.17.2007).

Image-18: The latest panoramic radiograph (03.31.2008)

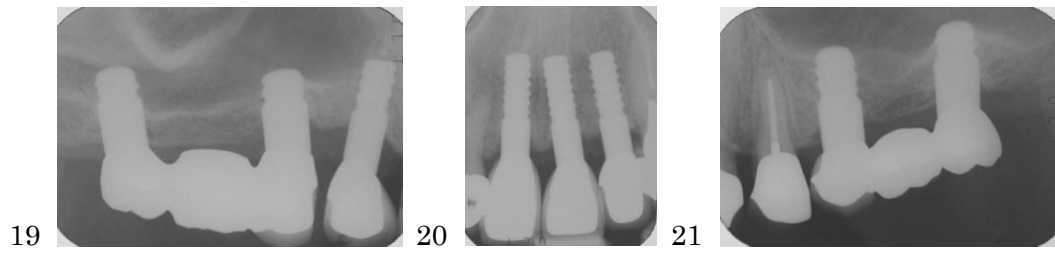


Image-19: Dental radiograph (03.13.2009) featuring the state 5 years and 8 months after the sinus-lift procedure

Image-20: Dental radiograph (03.13.2009) featuring the state of implants after a year and 2 months after the placement of the final structure.

Image-21: Dental radiograph (03.13.2009) featuring the state 2 years and 2 months after the socket-lift procedure.

16. A case where a trephine bur was used for maxillary sinus elevation

Director of Tokyo Kagawa Dental Clinic

Toshiaki Miyazawa

The maxillary sinus floor elevation methods have often been conducted with the use of techniques such as the socket-lift or sinus-lift, but we present here a case whereby a trephine bur was used to elevate the maxillary sinus, in preparation for the installation of one-piece type implant.

Patient: 58 year-old male

Chief complaint: Requested implantation to the missing teeth at positions No. 12 and 14 that had been lost due to root fracture.

Treatment plan: Conduct segmented tooth extraction of No. 14 tooth starting from the two buccal roots, and then No. 12 tooth. During the healing period of the extraction sockets, conduct maxillary sinus elevation, using trephine bur on No. 13 position where the height of the bone was deemed inadequate. Install one-piece type implant after a period given for bone regeneration

The segmental extractions of No. 14 tooth from the two buccal roots, followed by No. 12 tooth were conducted. These had been the subjects of root fracture (Image-1) as they had been acting as anchor teeth for the loss of No. 13. The bone of the extraction sockets were shown to have healed readily (Image-2,-3), so gingival incision, and detachment were conducted using the standard procedure under conduction anesthesia (Image-4), and drilled into the cortical bone of the maxillary sinus with great precaution to avoid perforating the schneiderian membrane with 8 mm diameter trephine bur (Image-5,-6). Trephine bur of 8 mm diameter was selected to construct implant cavity for the installation of 4 mm implants, so that it had 2 mm excess in space. The bone fragment that was curved out with trephine bur was applied to carefully elevate the floor by roughly 4 mm. The extent of elevation was chosen with reference to the blood circulation available, and the degree in which it was still in sufficient contact with the surrounding alveolar bone (Image-7,-8).

The indentation formed from the elevation of the bone was covered by a resorbable membrane in preparation with GBR (Image-9). It was then sutured to complete the surgical procedure (Image-10).

Image-11 shows a panoramic radiograph after the surgery. It shows that the sinus floor to have been elevated by roughly 4 mm, and that a sufficient contact with the surrounding alveolar bones to have been achieved with favorable progress, without problems arising such as nose bleeds. Image-12 and 13 features the state of the oral cavity, six months after the surgery in the way of a photograph and a panoramic radiograph. From these images, the bone plane lying adjacent to the maxillary sinus to draw a smooth curve and is shown to be integrated with the surrounding alveolar bone with the alveolar bone to be retained at the same height. It also showed the absence of any abnormalities including sinusitis.

The one-piece implant was then installed after confirming the intactness of the alveolar bone after the usual procedure of gingival incision and its detachment, under conduction anesthesia. 4SS implant was installed, and the flap was sutured up to complete the surgical procedure (Image-15,-16). Image-17 features the radiograph straight after the implant installation. Although it was installed slightly more towards the posterior region than planned, the implant body position was confirmed to be inserted into

the elevated bone structure, and has been showing good progress since.

Observation

The staged approach that was described here is one where the subjective area was small, and one that did not require any bone filling agents. Thus the risk of infection can be considered to be relatively low even if slight perforation is made on the schneiderian membrane. The only disadvantage is that it can only be applied to a limited number of indications and is less flexible than the socket-lift method. This case example was the first attempt in applying the staged approach, therefore its applications to more cases will be required to confirm its reliability.

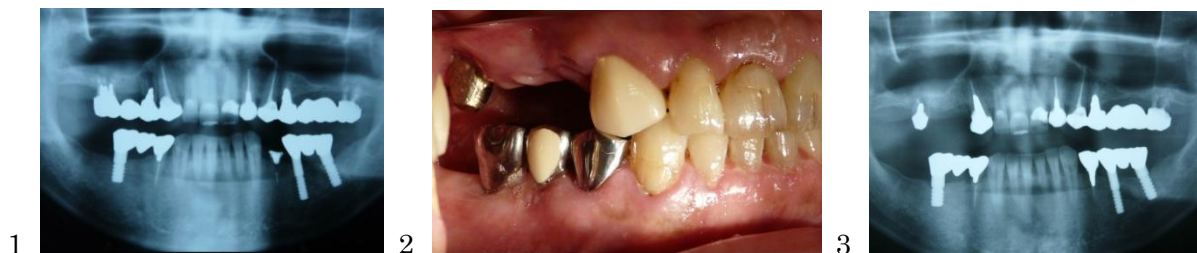

Image-1: Panoramic radiograph that featured the root fracture of No. 12 and 14 teeth that had been used as anchoring teeth for bridge prosthesis.

Image-2: Image of the oral cavity, ten months after the segmental and normal extraction.

Image-3: Panoramic radiograph, ten months after the segmental and normal extraction.

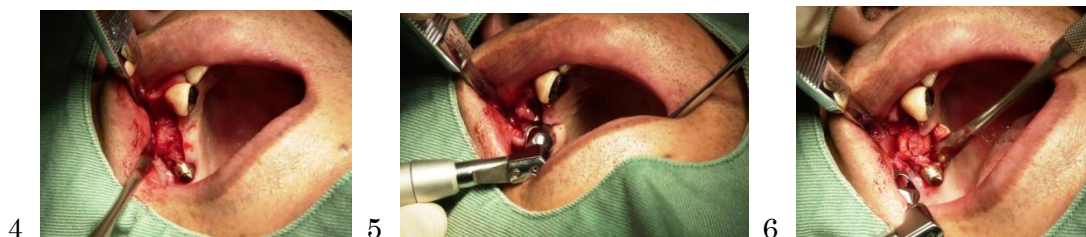

Image-4: The mucoperiosteal flap was incised and then detached under conduction anesthesia.

Image-5,-6: Images taken at the time of drilling to reach the cortical bone of the maxillary sinus with 8 mm diameter trephine bur.

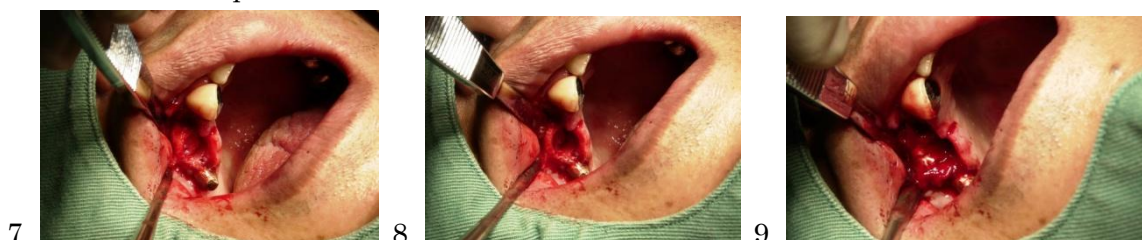

Image-7: Image at the time of elevating the bone fragment that was extracted with trephine bur towards the sinus.

Image-8: Image at the time of further elevation of the bone fragment to roughly 4 mm above what had been originally decided with respect to the extent of blood supply to the bone.

Image-9: Image at the time of covering the indentation, made for the elevation, in preparation for GBR procedure.

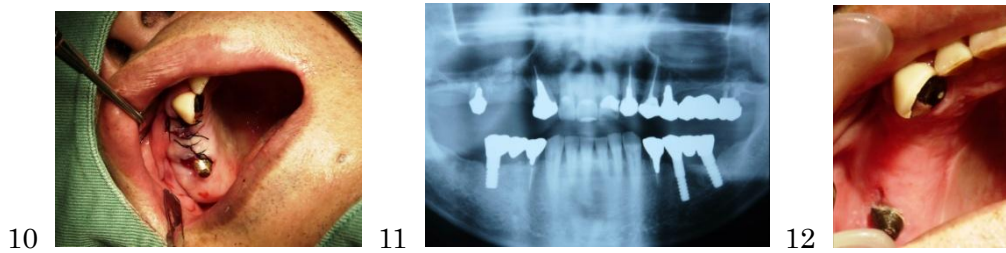


Image-10: Operation completed with suturing.

Image-11: Post-operative radiograph

Image-12: Image of the oral cavity six months after surgery.

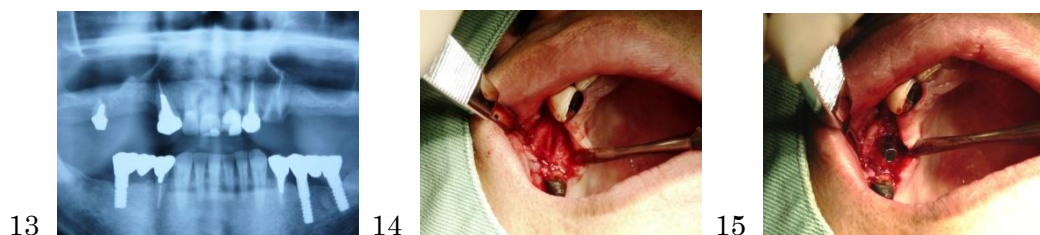

Image-13: Panoramic radiograph six months after surgery.

Image-14: The gingival incision and detachment were conducted, under conduction anesthesia

Image-15: One-piece type implant was installed following standard protocol.

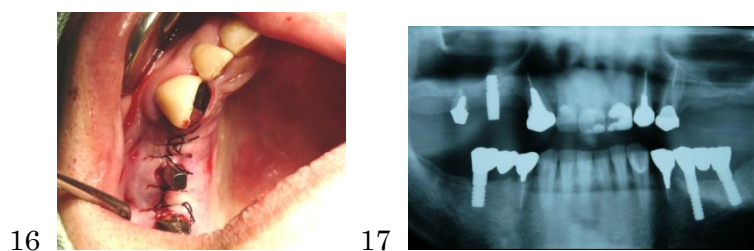


Image-16: Suture to complete the surgery.

Image-17: Panoramic radiograph featuring the state straight after the implant installation.

17. A case of horizontal alveolar bone extension using alveo-wider method

Professor of Dental Surgery, The Nippon Dental University Hospital

Masayori Shirakawa

Department of Dentistry, Oral and Maxillofacial Surgery, Machida Municipal Hospital

Fumio Ata

Assistant Professor of Dental Surgery, The Nippon Dental University Hospital

Kazumasa Yoshida

Introduction

The implant treatment has become a significant part of the clinical dentistry in the recent years. However, there are still cases where insufficient bone quantity poses as a problem to simple implantation procedures. In performing implant treatment to an atrophied alveolar bone, alveolar ridge augmentation procedures have to be conducted, that require procedures such as: autogenous bone graft, GBR, use of biomaterials, or distraction osteogenesis. Amongst these, the alveolar extension methods that apply distraction osteogenesis technique that can also result in the augmentation of the surrounding soft tissue have been of growing interest in the recent years.

The concept of distraction osteogenesis was established by Llizalov in 1951, where the method using the external fixator was developed^{1), 2)}. The first clinical application of this technique was by Chin³⁾ in 1996 for a vertical alveolar distraction osteogenesis, and this acted as a trigger for reports of implant treatments that were conducted concomitantly with vertical or horizontal alveolar distraction osteogenesis.

The notable properties of this technique are: it does not require bone graft; the extension can also involve the surrounding soft tissues; the many advantages as summarized in Table-1; bone augmentation predictability is relatively high compared to other techniques; with a high implant treatment success rate.

Quantity of bone extension

The ideal bone extension quantity for an alveolar distraction osteogenesis is 0.5 mm to 1.0 mm per day^{4), 5)}.

The alveolar distraction osteogenesis that are considered to be relatively small in terms of extension distance, and where the blood supply is poor, the extension is conducted 0.2 to 0.3 mm per day, and in the case of normal alveolar distraction osteogenesis, the rate is 0.4 to 0.5 mm/day. In terms of pain management, the extension frequency should ideally be conducted in segments than once a day.

Advantages	<ul style="list-style-type: none">● The surrounding soft tissues that line the bone are also subjected to growth extension.● Does not require donor site, and the surgical invasion is relatively small● The degree of bone extension can be controlled● The soft tissue treatments that surround the bone are relatively simple● The risks of dehiscence, infection and bone resorption are relatively low.● The neonatal bone can be developed within a short period of time in the space
------------	--

	<p>between the transport bone segment and the basal bone.</p> <ul style="list-style-type: none"> ● Lower risk of bone resorption after the distraction osteogenesis compared with other methods. ● The stabilization of bone fragment is secure due to the use of titanium plate. ● Highly predictable augmentation procedure enables an implant treatment with high success rate.
Disadvantages	<ul style="list-style-type: none"> ● The splitting osteotomy to a narrow alveolar ridge is highly complex, and skills are required to perform this technique. ● The blood flow from the periosteum to the transport segment is intercepted as osteotomy is required. ● The patient themselves have to perform extensions with the driver, therefore the management is relatively difficult ● Sense of discomfort of the external fixator attached, and the screws can cause pressure ulcer to the alveolar mucosa. ● The extension machine is relatively expensive.

Table-1 Advantages and disadvantages for an alveolar distraction osteogenesis

Classes	Definition	Bone augmentation procedures
Class I	Buccolingual loss of tissue contour with a normal apicocoronal height	Horizontal alveolar distraction osteogenesis, veneer graft, split crest
Class II	Apicocoronal loss of tissue with normal buccolingual contour	Vertical alveolar distraction osteogenesis, inlay graft, GBR
Class III	Loss of both buccolingual and apicocoronal dimensions	Saddle graft, GBR

Table-2: The Seibert classification of the ridge deformities

Latency period

The period between the osteotomy to the beginning of the alveolar distraction osteogenesis are known as the latency period, which is usually a week for a grown adult. The extension of this period has been reported to improve the results of the bone formation after distraction osteogenesis, and there have been reports that the period should be increased to two weeks instead of one in the cases of where the transport bone segment conditions are unfavorable ⁶⁾.

Consolidation period

A period for bone development is usually determined once the planned bone extension has been completed. This period has been recommended in the literature to be 6 to 12 weeks, but we consider the period that is 4 to 6 times that taken for the extension to be necessary.

Alveo-Wider: the device designed for the horizontal alveolar ridge distraction

This device was developed with the objective to augment the alveolar ridge and for surgery before prosthesis installation in conjunction with endosseous placement of implants (Fig.1). It is a system whereby the atrophied alveolar bone is split in the buccolingual direction, and extends in terms of the

width. It is applied to cases where the alveolar bone atrophy has manifested as a result of external injury, congenital disorder or periodontal disease.

Alveolar-wider is applied for Class I indications with the Seibert classifications (Table 2).

The alveolar-wider is constructed of a pure titanium mesh plate that shows elasticity, and the distraction screw that was designed to be positioned at its centre. The titanium plate is fixed by microscrews, also made of titanium, (diameter 0.9 mm, length 2, 3 or 4 mm) to be placed in between the transport segment and the natural bone. The distraction screw is a titanium-made screw that is 2 mm in diameter and 12 mm in length and is positioned in such a way that it pierces through the transport segment and contacts the bone on the lingual side. By rotating with a specialized screw driver, the distraction screw acts as a pivot on the buccal bone to open up the transport segment.

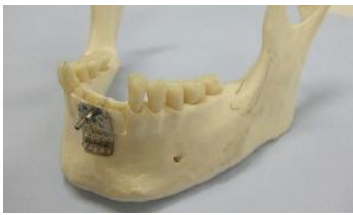

Figure 1: Model of the jaw fitted with an alveolar-wider

Application of Alveo-Wider

1) Incisional detachment

Alveolar ridge incision is applied following the split crest method to incise into the mucosa. Regarding the mucosal detachment, a full thickness mucoperiosteal flap should be formed on the buccal side, with a sufficient opening to conduct osteotomy.

2) Osteotomy

- a) Split the alveolar ridge into two in buccolingual direction with a thin, micro-electronic saw.
- b) Apply a longitudinal incision to the buccal cortical bone to the depth that matches the length cut in a).
- c) Add a horizontal osteotomy only to the cortical bone of the buccal base (preserve the cancellous bone).

3) Trial and fixing of the mesh plate

Curve out the mesh plate in a shape that corresponds to the box-shaped transport segment formed from osteotomy. Having preserved the bone on the lingual side, drill into the center of the transport segment on the side closer to the alveolar ridge, with a drill designed for a 2 mm diameter distraction screw. Temporarily fix the Alveo-Wider and simultaneously fix the mesh plate with screws. Then conduct greenstick fracture in the region of osteotomy with a narrow bone chisel.

4) Operative confirmation of the machine, and suture

An extension trial was conducted to assess the functioning of the Alveo-Wider. Once confirming there to be no problems, the distraction screw was restored to its original position, and the rod portion was pierced through a hole constructed in the mucoperiosteal flap. The wound was then closed with mattress suture.

5) Postoperative management, and distraction osteogenesis

After 7 to 10 days latency period, the bone extension was conducted twice daily, by 0.4 mm per day (0.4 mm per one rotation). In the cases where the osteotomy is replaced by the greenstick fracture, the

observation period should be lengthened by about a week. If the wound healing process is eventful, the stitches can be removed within few days, and the extension rate to a maximum of 0.8 mm per day. Bone extensions should be evaluated with X-ray radiograph of the occlusion. Overcorrection may be necessary to prevent the occurrence of bone height relapse at the end of the consolidation period.

6) Confirmation of the bone maturation and withdrawal of Alveo-Wider

Consolidation of the bone structure should be confirmed with the use of radiograph of the occlusion and probing with the tip of an injection needle after six to eight week period. The extension device can be removed after 3 months of consolidation period. Implant installation can be conducted either concurrently with this removal or as a secondary operation after the bone and mucosa have healed.

Reference

- 1) Lizarov GA. The tension-stress effect on the genesis and growth of tissues. Part I. The influence of stability of fixation and soft-tissue preservation. Clin Orthop. 1989; (238); 249-281.
- 2) Lizarov GA. The tension-stress effect on the genesis and growth of tissues. Part II. The influence of stability of fixation and soft-tissue preservation. Clin Orthop. 1989; (239): 263-285.
- 3) Chin M, Toth BA. Distraction osteogenesis in maxillofacial surgery using internal devices: Review of five cases. J Oral Maxillofacial surgery, 1996; 54: 45-53.
- 4) Nosaka Y, Kobayashi M, Kitano S, Kimori T. Horizontal alveolar ridge distraction osteogenesis in dogs: Radiographic and histologic studies. Int J Oral Maxillofacial implants 2005; 20: 837-842.
- 5) Oda T, Sawaki Y, Ueda M. Experimental alveolar ridge augmentation by distraction osteogenesis using a simple device that permits secondary implant placement. Int J Oral Maxillofacial Implants 2000; 15:95-102.
- 6) Aida T, Yoshioka I, Tominaga K, Fukuda J. Effect of latency period before mandibular distraction on early osteogenesis in rabbits. Japanese J Oral Maxillofac Surg. 2001; 47: 507-516. (Japanese)
- 7) Manabe M, Kurachi Y. Vertical Alveolar Ridge Augmentation by Distraction Osteogenesis. J Showa Univ Dent Soc. 2003; 23: 289-292. (Japanese)
- 8) Cano J, Campo J, Gonzalo JC. Consolidation period in alveolar distraction: A pilot histomorphometric study in the mandible of the beagle dog. Int J Oral Maxillofacial Implants. 2006; 21: 289-292.

A case example

Patient: 55 year-old female

Chief complaint: Loss in alveolar crest bone quantity due to external injury to No. 9 and 10 teeth.

Current symptoms: Class I state of the alveolar ridge according to Seibert Classifications. Horizontal atrophy of the alveolar ridge in the labial, buccolingual orientation, that is in an extensive knife-edge state.

Bone width: 3.1 mm.

Treatment plan: As a result of clinical evaluation, a stage-approach was planned with expansion of the alveolar bone width, and a horizontal alveolar distraction osteogenesis in conjunction with implant installation.

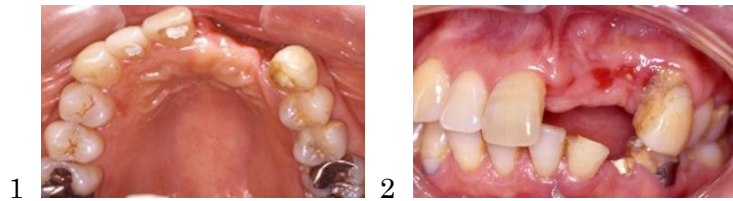


Image-1,-2: Image of the oral cavity. Both alveolar bone and mucosa were lost in a traffic accident, and an extensive cicatrix conjuncture of the gingivae can be observed.

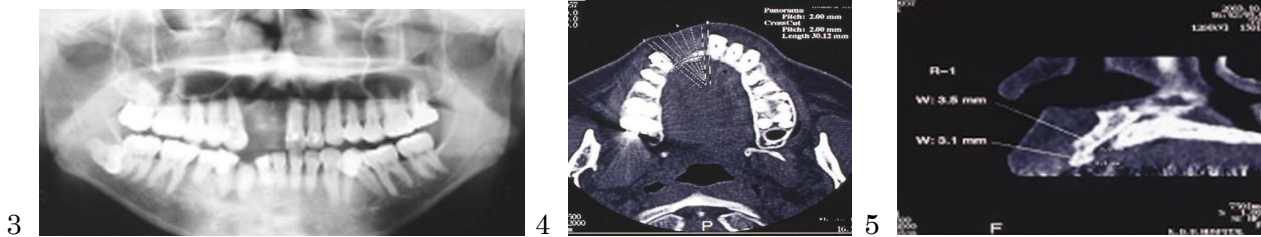


Image-3,-4,-5: Preoperative image evaluation. It was confirmed from CT scan that alveolar bone width only had 3.1 mm remaining.

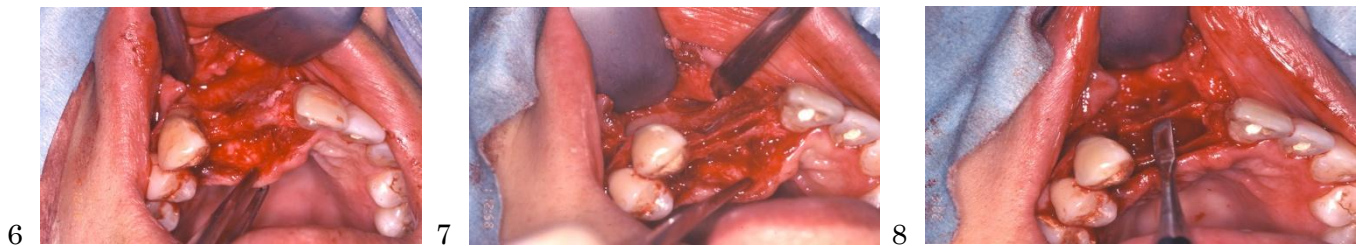

Image-6,-7,-8: Perioperative image of the oral cavity. Horizontal splitting of the alveolar bone is shown.

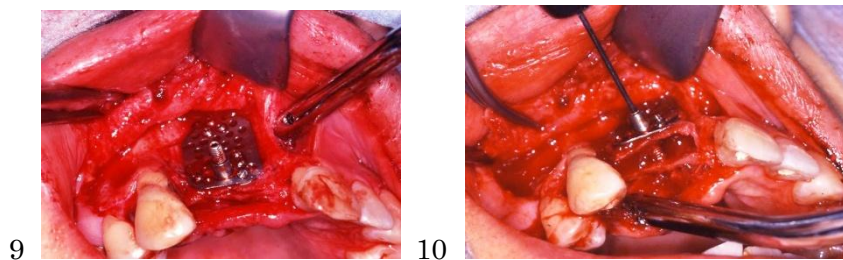


Image-9,-10: Setting the alveolar-wider device, and functional testing of the driver are shown. The key here is to limit the incision to the point of greenstick fracture on the basal plane, and to not detach it completely. The extension was conducted by one rotation a day, which resulted in an expansion of 4 mm in alveolar width after 10 days.

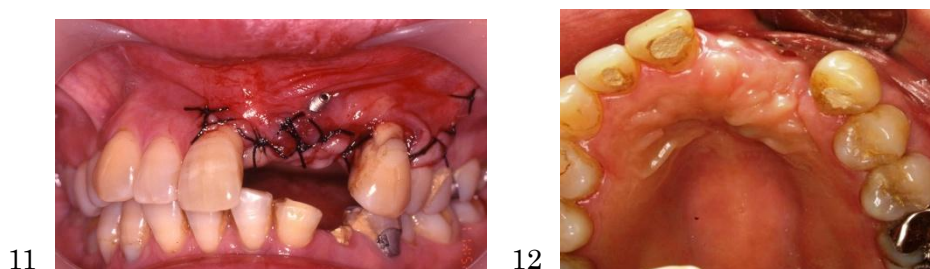


Image-11: The device was removed, and sutured to allow healing to take place.

Image-12: Image, 30 days after the surgery. The mucosal membrane was also expanded.

18. Establishing a suitable oral environment to prolong implant survival

Director of Hayashi Dental Clinic, Fukuseikai Medical Corporation
Fukui Implant Center
Masato Hayashi

The state of oral hygiene is highly influenced by the technique used, the frequency, and the time of the day when conducting the clean as well as the intraoral environment. The demolition of the oral cavity hygiene can be a result of either systemic or local factors. The systemic causal factors include metabolic syndromes, circulatory disorders, blood disorders, bone disease, or endocrinopathy; while local factors include, the location of the frenulum, attached gingiva, the quality and quantity of the saliva, prosthesis failure, occlusion, periodontal disease, unfavorable tooth alignment, and presence of wisdom tooth. Even if the natural tooth has been replaced with implants, the alveolar bone resorption is induced in the presence of these factors. In such cases, locating the source and resolving these underlining problems becomes a vital requirement.

In order to maintain a state of oral hygiene, daily clean by the patient themselves or via means of professional mechanical tooth cleaning (PMTTC) should be requested in order to overcome the limitations such as with the tooth brushing by the patient themselves. Establishing an oral environment is vital to maintain a satisfactory level of oral hygiene.

A case is presented here in which the oral environment was improved upon implantation to the molar region in conjunction with GBR, sinus-lift and vestibuloplasty.

Case 1.

Patient: 36 year-old female

First admission: June 16th 2003

Chief complaint: masticatory disorder due to the lack of No. 2 and 3 teeth.

Medical history/ family history: Nothing to note

Present disease history: No. 2 and 3 teeth were extracted at a previous dental clinic, and the patient was offered a placement of a denture, but came to this clinic with a request for implant treatment.

Current symptoms:

Systemic: 156 cm in height, 42kg weight

Oral: missing No. 2 and 3 teeth. The buccolingual bone width and region of the gingival attachment was relatively narrow (Image-1a,b). No abnormality symptoms present from a radiographic evaluation, and the distance from the alveolar ridge to the mandibular canal was roughly 11 mm.

Treatment plan: Planned prosthetic restoration with implant placement.

Implant installation to positions No.2 and 3 with GBR:

Apply, under conduction anesthesia of 2% xylocaine 3.6 ml, an incision line to the alveolar ridge, and a longitudinal incision in a fan-shape from the distal corner of the second mandibular left premolar and mesial corner of the third left molar to form and detach full thickness mucoperiosteal flap (Image-3). As

the buccolingual width of the alveolar ridge had been 4 mm, the drilling was conducted with top-down treatment for the installation of AQB implant that was 4 mm in diameter and 17 mm in length (8 mm coating, and 9 mm abutment) (Image-4). GBR technique was applied to this case as the buccal bone wall of the implant had become a deficit, and could not prevent the exposure of the implant coated surface.

First, the cortical bone in the surroundings were pierced through to form perforations to the medulla to induce bleeding onto the bone surface (Image-5, a-c). Next, the autogenous bone fragments were filled in a way that cover the exposed surface and then placed a resorbable membrane (Biomend™) (Image-6 a-c).

Relief incision was added to the labiobuccal side before the closing with mattress suture and simple suture methods using gore-tex suture (CV-5, W. L. Gore Associates Inc.), to complete the implant installation and GBR (Image-7,-8).

Observation:

After each meal, oral cleansing with 0.2 % chlorhexidine (chlorhexidine gluconate, Kenei Pharmaceutical) and applied tissue repair stimulant (Solcoseryl ointment) for the restoration of the wound, and this was continued for two weeks after the surgery. Barrier membrane was found to be completely covered (Image-9).

The perio-test results surrounding the two implants inserted two months following surgery were found to be -4 to -5. The temporary crown was then fabricated and vestibular extension was conducted.

The vestibular extension of the surroundings of No. 2 and 3 implants

First, under conduction anesthesia of 2 % xylocaine 1.8 ml, an incision line from the attached gingival region to the border of the movable tissues was drawn, followed by an apical incision of partial thickness on top of the periosteum, then a periosteal incision was made at the point of reaching the vestibule of the mouth. Then full thickness incision from the periosteal incised region was formed, further towards the apex by 1 to 2 mm (Image-10 a-c). The incised epithelial mucosa was wrapped up towards the root apex, and was connected to the reflected apical periosteum (Image-11).

Next, free gingiva was grafted. An incision line was applied to a location 2 mm from the palatal tooth cervix region to No. 3 and 4 positions, and extracted a square of the gingiva by forming an incision, which was then closed with repetitive sutures. The transport fragment was then placed on top of the periosteum and fixed with suture (Image-12).

Finally a temporary crown was mounted with temporary cement application, and the donor site was protected by fixing a periodontal pack.

Progress:

The postoperative state of the oral cavity is shown (Fig-13). The superstructure was fabricated once the mucosa had healed (Image-14). Three years and two months had passed since the placement of the superstructure, with no presence of large red patches, and satisfactory progress had been made with the retention of the size of the vestibule.

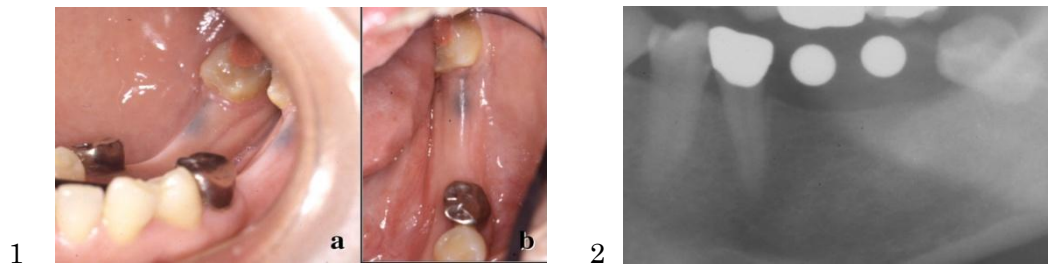


Image-1a,b: Image of the oral cavity before surgery

Image-2: Panoramic radiograph before surgery

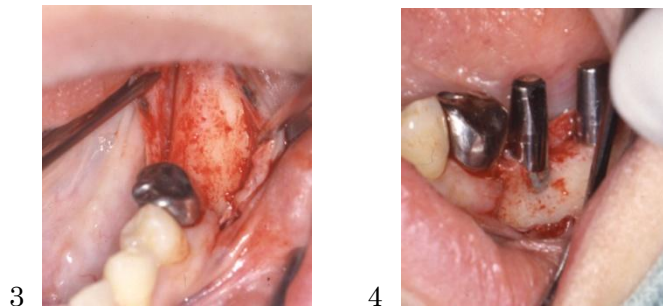


Image-3: Incision making, and elevation

Image-4: Installation of implant body

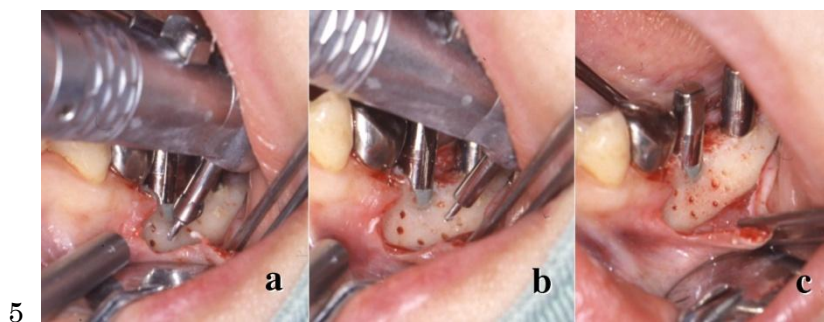


Image-5 a,b,c: Decortication and punching holes in jaw bone

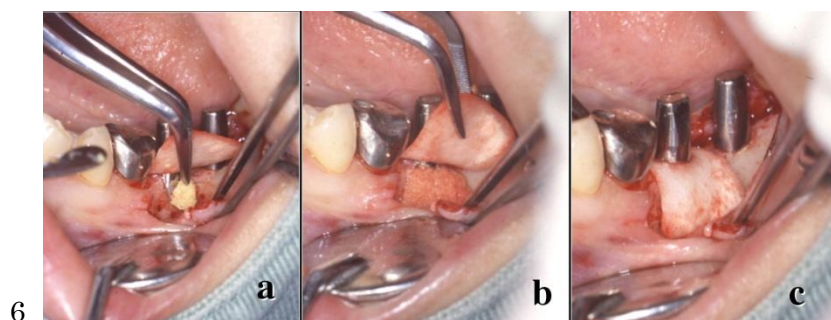


Image-6 a,b,c: Placement of allograft and membrane.

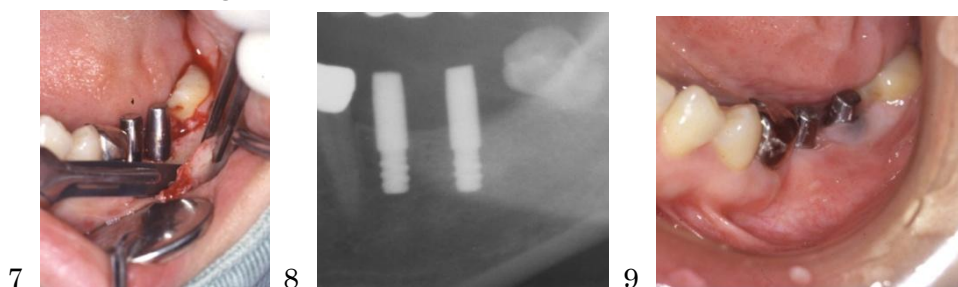


Image-7: Application of release incision

Image-8: Panoramic radiograph straight after the implant installation

Image-9: Image of the oral cavity two months after the surgery.

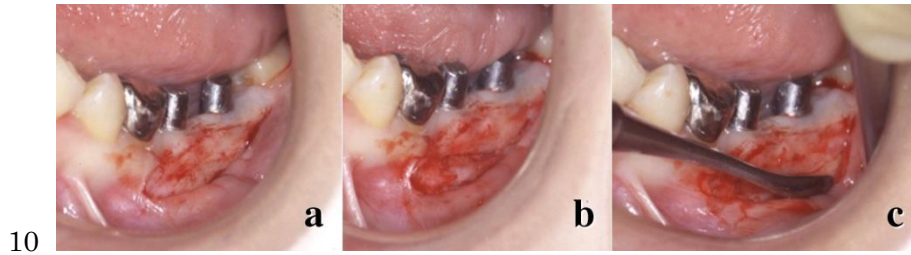

Image-10 a,b,c: Vestibular expansion (full and partial thickness incision)

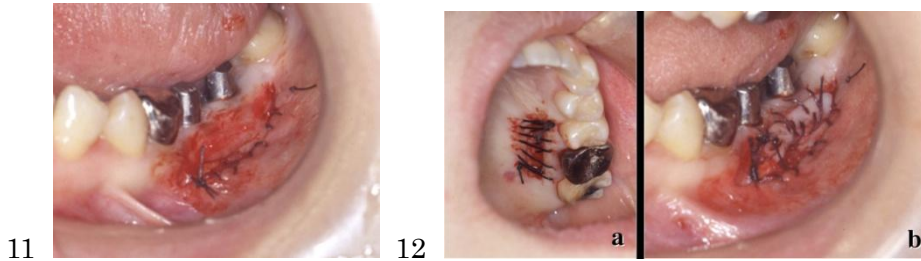


Image-11: Vestibular expansion (suturing epithelial connective tissues and apical periosteum together)

Image-12 a,b: Vestibular expansion (free gingival graft)

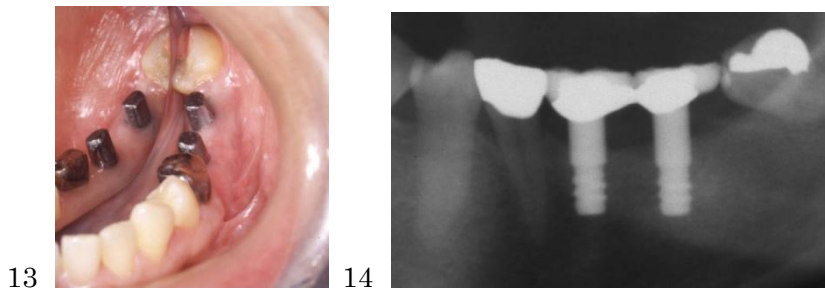


Image-13: Image, two months after the vestibular expansion surgery.

Image-14: Radiograph after the placement of the final prosthetic restoration

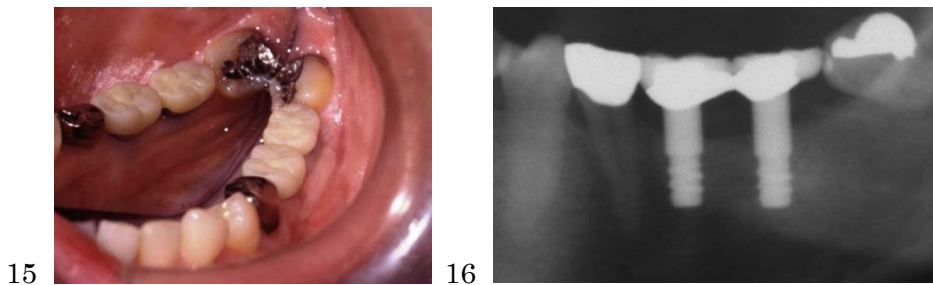


Image-15: Image of the oral cavity three years and two months after the vestibular expansion surgery.

Image-16: Panoramic radiograph three years and two months after the vestibular expansion surgery.

Case 2.

Patient: 41 year-old female

First admission: January 6th 2003

Chief complaint: Masticatory disorder due to lack of No. 3 to 5.

Medical history/ family history: Nothing to note

Present disease history: The patient was offered placement of a full denture at the previous dental clinic, but came to this clinic requesting implantation.

Radiography analysis: No symptoms of inflammation, swelling or cyst could be observed. The vertical bone width was less than 2 mm at No. 3 and 4 positions.

Systemic features: 164 cm in height, 56 kg weight.

Current symptoms:

Oral: Missing No. 2 to 5 teeth.

Treatment plan: Prosthetic restoration with implants to the positions No. 3 to 6.

Treatment method

GBR and sinus-lift technique were conducted concomitantly via lateral wall approach, in conjunction with implant installation, followed by superstructure fabrication after a non-loading period.

Three AQB two-piece type implants were used (4102 for positions No. 3 and 6; 4122 for No.4). As two implants to No 3 and 4 positions could not obtain primary stability, titanium plate was applied as a connective fixing device to restrict the implant movements (Image-2,3). At the maxillary sinus floor elevation procedure, the bone augmentation was conducted with autogenous bone and bone filling agents, and the bone window was covered with a PRP (platelet rich plasma) membrane before the placement of a non-resorbable membrane for GBR (Image-4,-5).

The perio-test of the three implants were monitored from time to time, and observed the micromotion of implants. All of the perio-test results had reached negative values, six months after the surgery, at which time the superstructure was fabricated (Image-6 a-c).

The vestibular expansion was conducted a year later, as this case as in the last case example had vestibules missing (Image-7). The state, one and a half month after the expansion is shown (Image-8).

There are no large red patches observed, and the size of the vestibule was shown to be maintained. Furthermore the radiograph featured favorable postoperative progress to be made (Image-9 a-f).

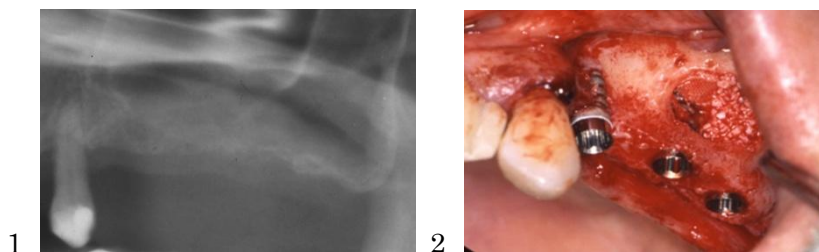


Image-1: Panoramic radiograph before surgery

Image-2: Implant installation

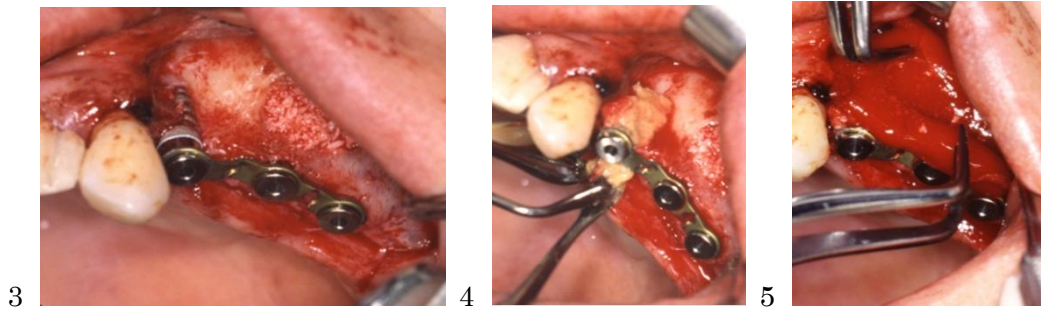


Image-3: Placement of titanium plate connection

Image-4: Allograft

Image-5: Placement of PRP (Platelet rich plasma) membrane

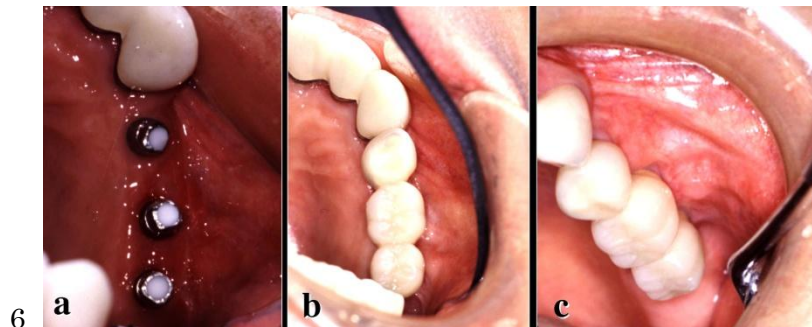


Image-6a,b,c: Image of the oral cavity at the time of abutment and superstructure placement

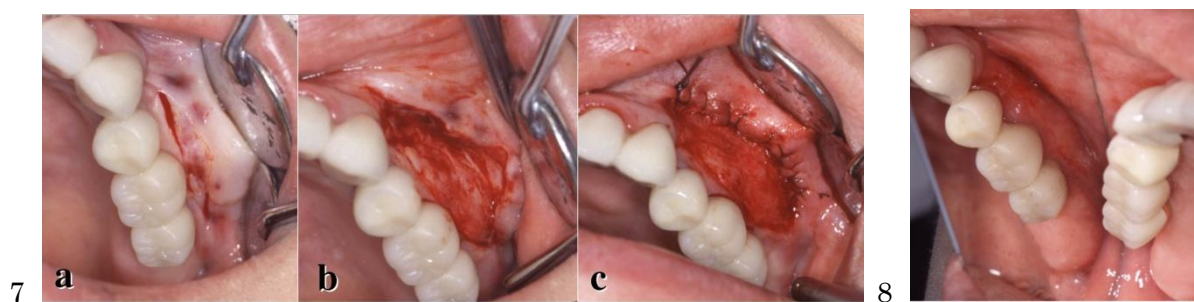


Image-7 a,b,c: Vestibular expansion

Image-8: Image of the oral cavity 1½ month after the vestibular expansion

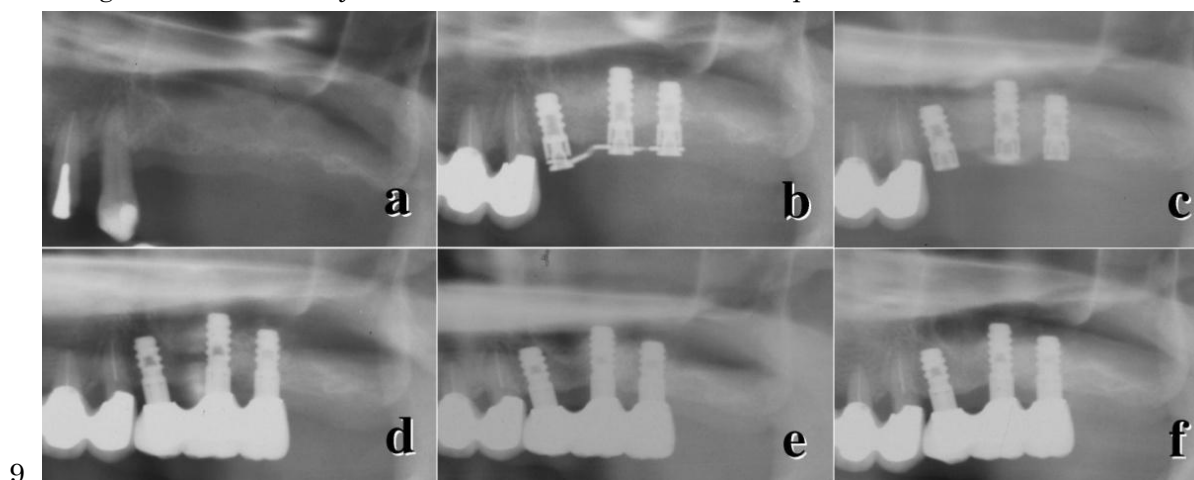


Image-9: Panoramic radiograph featuring the treatment time course

- a. Before treatment
- b. After surgery
- c. After titanium plate removal
- d. After superstructure placement

- e. Two years after the superstructure placement
- f. Five years after the superstructure placement

Summary

Implant treatment has advanced at an astonishing rate, from a temporary occlusal restoration to long-term medical care by the establishment of osseointegration. This has become a cornerstone in the maxillofacial surgery in the recent years and enabled it to establish a firm ground in the field of dentistry. The weaknesses in implant treatment still remains that are largely divided into those damages to the surrounding structures resulting from peri-implantitis, and fractures of the implants and its accessories from an incompatible occlusion.

Implant treatments that are devoid of supplementary surgeries to correct the dimensions of the bone and periosteum in the preparations for the installation is not possible in some of the cases therefore gaining experience and improvements in surgical techniques are an essential requirement. Additionally, where a release incision is applied, further narrowing of the vestibule can result, worsening the oral environment with food remnants and thus leading to an induction of peri-implantitis.

In taking into full consideration the characteristics of HA coating implants, it can be concluded that the vestibular extension plays a key role to establishing an oral environment that is suitable.

Additionally, by reflecting on the fact that the starting point of the implant treatment from the superstructure placement, the importance of the long-term control of occlusion can be reconsolidated.

19. A case where a vestibular extension surgery was conducted after bone regeneration, in conjunction with implant installation

Oral-Maxillofacial Surgery, Dentistry and Orthodontics,
The University of Tokyo Hospital

Yuki Kanno

Instructor of Oral-Maxillofacial Surgery, Dentistry and Orthodontics,
The University of Tokyo Hospital

Hideto Saijyo

The problem that often arises after the bone augmentation procedure is the narrowing of the vestibules. In such cases, the movable, free gingiva gets into the area of implant insertion, subsequently affecting the state of oral hygiene and preventing an esthetic finish to be achieved. It is desirable for the state of the gingiva to be firmly attached to the periosteum in a similar manner to those of the natural teeth. In order to achieve this state, procedures such as vestibular expansion (vestibuloplasty) are conducted.

A case is presented here, in which bone regeneration was done to a patient who had lost teeth and the alveolar crest in a traffic accident. Vestibular expansion was applied in preparation for implant installation for the vestibule had narrowed.

Patient: 33 year-old male

First admission: June 2007

Chief complaint: Loss of estheticism due to loss of anterior teeth

Medical history/ family history: Nothing to note

Present disease history: Injured in a traffic accident, June 2007 (Image-1). Open reduction internal fixation (ORIF) procedure had been performed to the left maxillary fracture at our department, in July the same year.

Current symptoms: Missing No. 5 to 8 teeth. Advanced case of vertical alveolar bone deficiency could be observed at the position.

Treatment plan: After a course of bone regeneration (titanium mesh plate and autogenous cancellous bone), conduct vestibular expansion if necessary and install two-piece implant.

A year after the ORIF procedure, bone regeneration was performed with the placement of titanium mesh plate, and autogenous cancellous bone, under general anesthesia. After an application of reverse bevel incision as shown in Image-4, and subperiosteal exfoliation, an extensive alveolar bone deficiency became apparent (Image-5). After a trial of titanium mesh plate, 0.4 mm in diameter, shaped for a suitable fit (Image-6), cortical bone extracted from the ilium of the patient was fixed alongside the titanium mesh plate with microscrews, and the cancellous bone from the right iliac crest was compacted on the titanium mesh interior (Image-7). A release incision was applied before closing the wound (Image-8). The postoperative radiograph and three dimensional CT (3D CT) image is shown (Image-9,-10).

Two months after the bone regeneration procedure, the titanium mesh plate was removed under local anesthesia, for outpatients, ready for the vestibular extension to be conducted. Favorable engraftment of the bone was observed (Image-11).

The extension technique was performed a month after the titanium mesh removal. The vestibular mucosa

was removed at positions No. 5 to 8, and after the mucoperiosteal flap was transferred to the apical side (Image-12,-13), artificial dermis (Pelnac®, Gunze) were placed to cover the exposed area of periosteum, and pressure dressing was applied by means of tie-over dressing technique (Image-15).

The two-piece implant installation was conducted a month after the vestibular expansion (Image-16 to -18). As planned, the 5102 type were installed to No. 6 and 8 positions, and 5122 to No. 5, and completing the surgery. The postoperative radiograph is shown (Image-19).

Two months following implant installation, porcelain bonded metal crowns were placed having finished the secondary surgery (Image-20,-21). The images feature the state three months after undergoing the vestibular extension procedure, where a slight regression of the mucosa can be observed, but since this is at the anterior teeth, it should not significantly affect the level of oral hygiene. Procedures such as free gingival graft and skin grafts are also effective in replacing vestibular extension technique however, since a donor site is required, a thorough deliberation is required.

In this case example, we were able to achieve favorable outcome with the application of Pelnac® for the vestibular extension procedure.

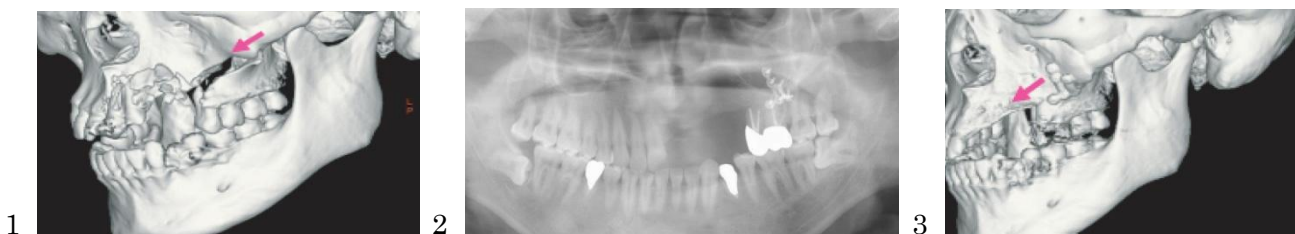

Image-1: 3D-CT at the time of first clinical evaluation. Lack of No. 5 to 8 teeth as well as the splintered fracture of the alveolar crest can be observed.

Image-2: Panoramic radiograph taken 10 months after the ORIF procedure. The mini-plate that was fixed to correct the fracture can be seen

Image-3: 3D-CT taken ten months after the ORIF procedure. Lack of No. 5 to 8 teeth is evident.

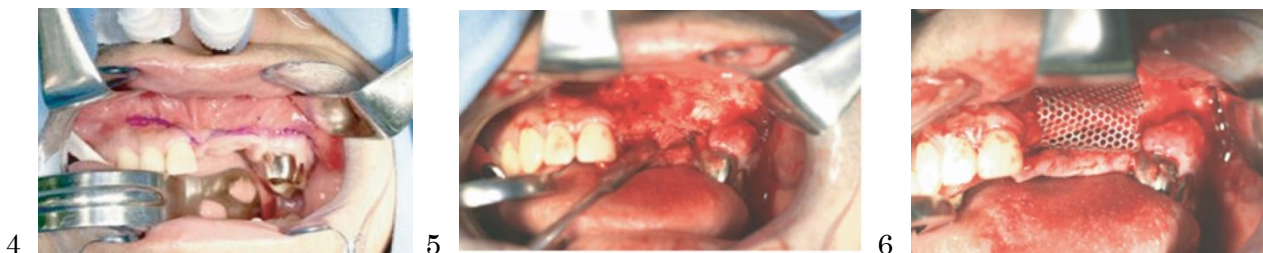

Image-4: Intraoperative image during bone regeneration operation. The mucosal incision was applied on the more labial side than the alveolar ridge.

Image-5: Image of the oral cavity after periosteum detachment.

Image-6: Titanium mesh plate fitting

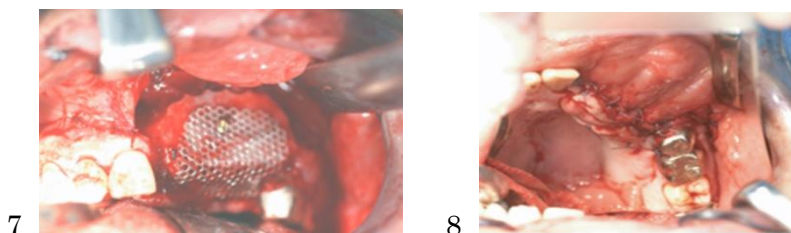


Image-7: The cortical bone extracted from the ileum was fixed with the titanium mesh plate using the microscrews, and the surrounding was compacted with cancellous bone.

Image-8: Image of the oral cavity after closing the surgical wound. Narrowing of the oral vestibule was evident therefore vestibuloplasty as a secondary surgery was planned.

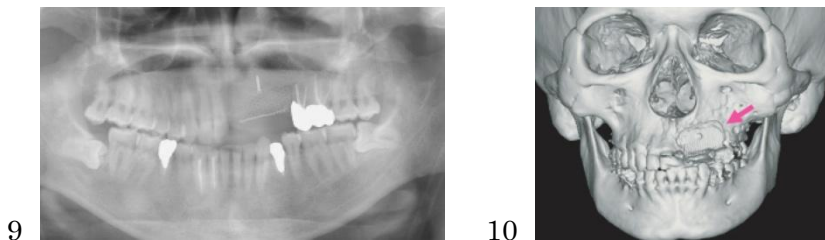


Image-9,-10: Bone regeneration therapy was performed and the postoperative panoramic radiograph and 3D-CT scan from it are shown.

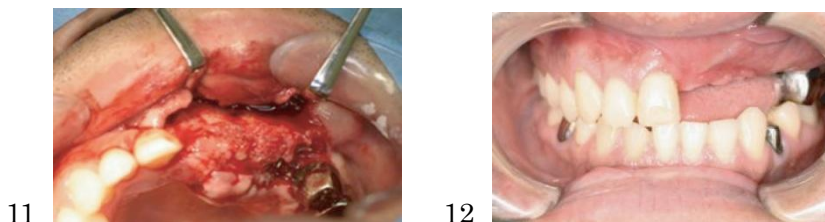


Image-11: Image featuring the oral cavity after the removal of titanium mesh plate. Satisfactory bone regeneration could be observed upon its uncovering.

Image-12: Image of the oral cavity during vestibular extension.

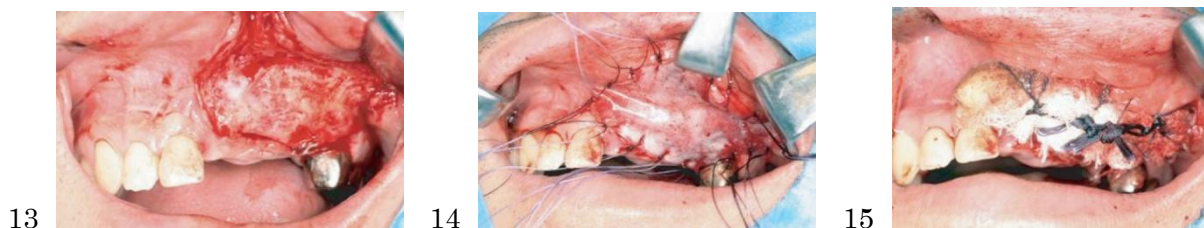

Image-13: The mucosal flap is lifted off the periosteum.

Image-14: Pelnac® was placed on the exposed area of the periosteum.

Image-15: After grafting the artificial dermis, pressure dressing was applied by the means of tie-over dressing technique.

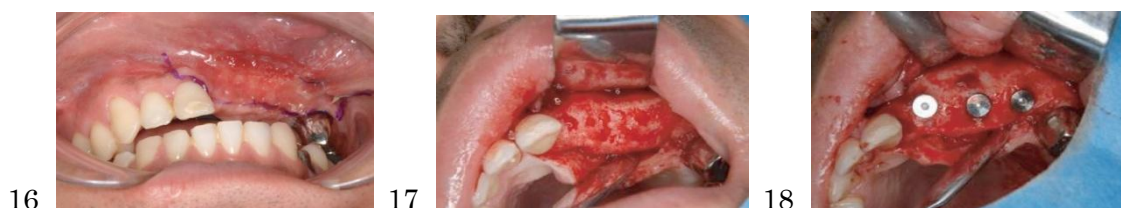

Image-16: Image of the oral cavity before implant installation. A reverse bevel incision line is drawn here.

Image-17: Image after periosteal elevation ready for implant installation.

Image-18: Image of the implant cavity directly after the two-piece type implant installation

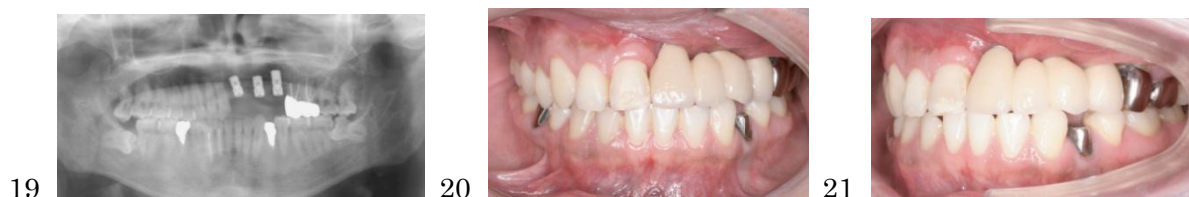

Image-19: Postoperative panoramic radiograph. Implants were able to be inserted as initially planned.

Image-20,-21: Image a month after the placement of porcelain bonded metal crown (from the front and the side). No inflammation of the surrounding structures can be observed.