

Chapter 3 Implant and prosthodontics

Professor emeritus at Okayama University
Atsushi Yamashita

I. Basic implant concepts

Medical care in the twentieth century has progressed in the form of a system that maintains a focus on the role of doctors and disease intervention, the so-called doctor/disease-oriented system (DOS). The DOS concept placed the disease at the center, and the doctor treated patients in a way that was believed by the doctor to be the best for the patient. However, this concept that placed emphasis on the doctor's discretion carried the danger of the doctor ignoring the views of the patient. Entering the twenty-first century, the paradigm shifted to the patient/problem-orientated system (POS) where the emphasis was on the patient, and treatment of the problems presented by the patient. Here, the patient's autonomy, right of self-determination, inviolability, and confidentiality were respected. Concepts such as quality of life (QOL) and informed consent were emphasized, and medical care evolved to emphasize avoidance of harm to the patient.

Where DOS treatment prevailed in prosthodontics, especially with crown prosthodontics emphasis was placed on the dynamic stability of prosthetic appliances for the replacement of missing teeth. Treatments largely involved inactivating the dental pulp of the abutment by means of mass removal of teeth, which may result in destruction or loss of biological tissues, without any regard for conservation of teeth. This often resulted in a poor long-term prognosis and led to the development of conditions such as periapical pathosis and root fracture.

With POS treatment, the merits and demerits of each treatment option, including no intervention, are discussed with the patient to arrive at a conclusion that the patient agrees to. The treatment options are underpinned by the idea of minimal intervention (MI), where mass removal of teeth is replaced by emphasis on reducing the burden on the patient, with minimal damage to the body during treatment. The idea of MI goes along with the emphasis on progress in dental adhesive materials, and advances in prosthodontics and conservation treatments. One clinical application, the resin-bonded, fixed, partial denture (adhesive bridge) was developed at the forefront of partial dentures that adhere to the POS concept.

Meanwhile, the implant prosthesis has the advantage of not encroaching upon neighboring units in the recovery of missing teeth. Therefore, the prognosis for the neighboring teeth is favorable, and treatment results in better outcomes than would be the case without intervention, such as extending the life expectancy of neighboring teeth. This favorable outcome of implant treatment has had a great impact and has been confirmed to support progress of the "8020 campaign" (have 20 teeth left at the age of 80), which was set up by the Ministry of Health and Welfare with the cooperation of with the Japan Dental Association, to improve the dental health of the nation. Implant treatment in keeping with MI can stop further degradation of teeth and has a positive effect on the QOL of patients with missing teeth. It is thus a treatment option that complies with the practice of POS.

There are additional benefits of implant treatment such as a high level of aesthetic restoration, and restoration of mastication and articulation.

However, a disadvantage of this high level of restoration of mastication is that it can lead to mechanical

problems with the implant itself. The greater mastication force can exert extensive stress on the implant, resulting in loosening of screws, implant body rupture and acceleration of bone resorption. Accordingly, in order to improve the prognosis, an extensive understanding of maxillofacial biomechanics and its basis - occlusion - are an essential requirement.

II. Establishing accurate occlusion

A. The survival rate of implant prostheses and reasons for failures

The implant prosthesis, if established correctly, complies well with the concept of POS-based medical care, and recent survival rates of these treatments have been 98% after five years, and 93% after ten years. In order to increase the twenty-year survival rate to over 50%, the figure for crown bridges, it is essential to take into consideration minute details and to implement these in practice to a degree far beyond that of previous prosthetic methods.

The factors that influence the prognosis of the implant prosthesis are as follows: missing teeth, quantity and quality of bone, contamination, and mechanical overload. The most prevalent concomitant disease is peri-implantitis, followed by mechanical overload, which is further divided into that affecting the superstructure and that affecting the body.

In this book, we will discuss ways to alleviate exertion of pressure on the prosthesis, in order to reduce the risks that may arise later.

As you likely already know, implants were not developed by research organizations such as universities, but by general clinicians. Consequently, there are only a limited number of well-designed prospective clinical studies evaluating factors such as occlusion of implant and parafunction. We hope that the universities and research organizations will take the incentive and follow up the outcomes of mechanical overload on the prosthesis and those affected by bruxism, and summarize these findings in a systematic review. It is important to note that lack of evidence does not indicate that the subject matter of “investigation of the nature of occlusion” or “what occlusion should be” should be taken lightly. I report here my findings from clinical practice and past prostheses, but must apologize for some of these, which may be based on poor scientific evidence.

B. An understanding of functional occlusion is essential in order to establish successful occlusion with an implant

The best documentation of physiological mechanisms involved in the stomatognathic system was compiled by Kawamura in 1972. He concluded that precise occlusion is established as a result of “an association between three components involved in functional occlusion: the masticatory muscles, temporomandibular joint and teeth/dentition, with the combined effect of neurological control by the brain and the central nervous system” (Fig. 3-3-1).

At the same time, Jankelson B. developed a method of measuring mandibular movement electrically. The Mandibular Kinesiograph, MKG, was used to objectively evaluate and differentiate correct occlusion from abnormal occlusion, which in turn showed the true nature of a physiological occlusion. In the past, assessment of occlusion had placed emphasis on the tooth occlusal pattern, the plane of the occlusal surface, and occlusal form, and it was believed that construction of a prosthesis on an articulator, that imitated jaw movement, would harmonize with the functions of the oral cavity. Present practice has

incorporated the functions of the neuromuscular system to arrive at physiological occlusion, and has led to progress. I trust that this paragraph will be of some use in the long-term practice of “implant treatments that are beneficial for patients”.

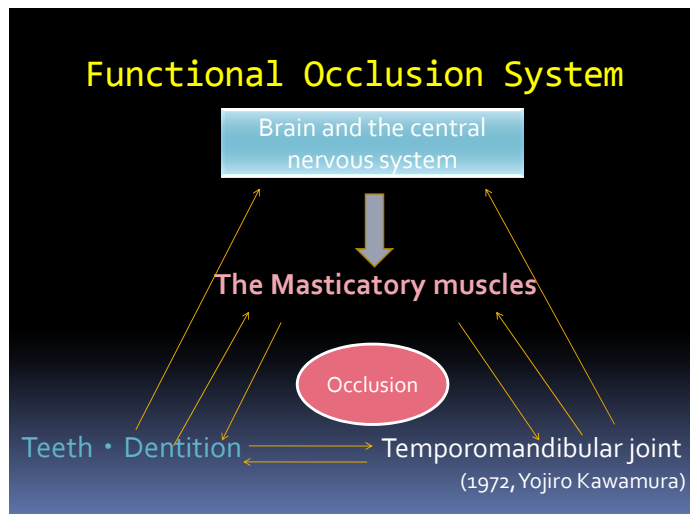


Fig. 3-3-1 Understanding the functional occlusion that is essential for establishing suitable occlusion with implant prosthesis

C. Why some successful occlusions collapse

A natural occlusion has to arise from the interplay of anatomically and physiologically functioning masticatory muscles and the temporomandibular joint, and the strong occlusion of the upper and lower mandibles is established by the coordinated activity of the central nervous system including the brain. The mandibular position in a functional occlusion system is sustained by being suspended by the masticatory muscles and the temporomandibular joint. Fig. 3-3-2 displays the natural mandibular position termed the “muscular contact position (MCP)” determined by Brill⁸⁾. He defined the MCP as “the mandibular position where the mouth is closed as the result of the lower mandible teeth slowly meeting the upper maxillary teeth, after establishing the muscular path of closure with slight muscle movement where the head has been held erect. This positioning of the jaw is the same as the maximum intercuspal position (centric occlusion) in terms of anatomical expression, and has been named from a physiological point of view.” This position has been verified physiologically to be present in 90% of people with complete permanent dentition. Brill stated that a physiologically adequate mandibular position is achieved in an occlusion where all the teeth contact with the opposing teeth at a time without dislocation of the mandible when gently closing the mouth after repeating a small open-and-close movement several times without contact of teeth, and the ideal occlusion is achieved when the MCP and the intercuspal position are matched. During this series of movements, each masticatory muscle shows coordinated movements, and the mandibular condyle is centered in the glenoid fossa. The MCP relative to the cranium is the ideal mandibular position. The chewing pattern encountered with the mandible in the MCP and intercuspal positions match is unlikely to vary (less than 1.0 mm), as seen in Fig. 3-3-2) and tends to be centered on the MCP⁹⁾. If this chewing pattern is presented at the time of investigation, it can be predicted that the implant prosthesis is unlikely to experience a lateral force or rotatory force, and therefore overload related to occlusion is not likely to become a problem.

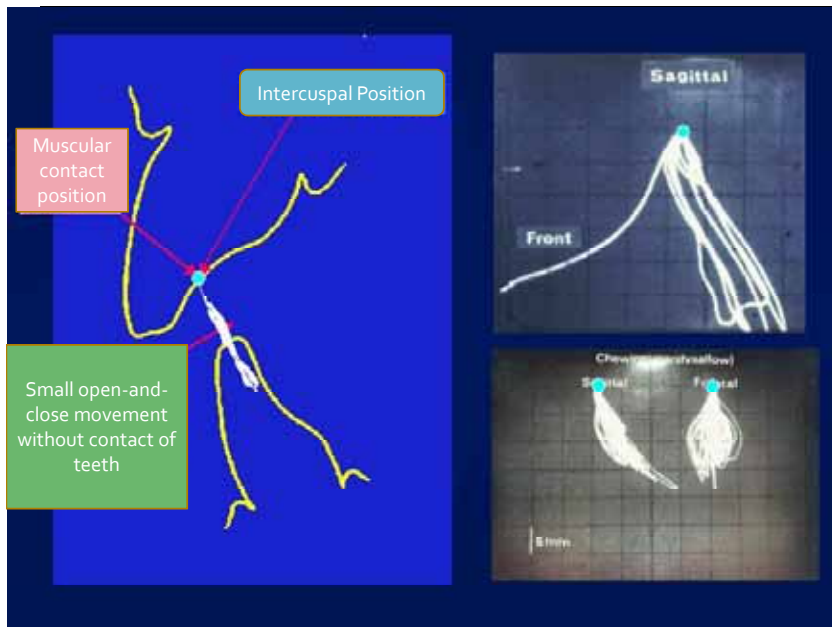


Fig. 3-3-2 Chewing pattern at the ideal mandibular position “muscular contact position” at which the muscular contact position and intercuspal position are matched

D. Why the mandibular position shifts relative to the skull

The mandible is held in a sling below the skull. Because of this, people with complete permanent dentition are prone to displacement due to the factors mentioned in Fig.3-3-3, which may alter the way in which the upper and lower teeth interact. In addition, emotional stress has been reported to influence the masticatory muscles and result in a shift in the lower mandible. An excessive inlay height of just a few microns can lead to activation of a recovery reflex that consequently results in unilateral mastication or a characteristic chewing habit in some individuals, and thus a shift in the position of the mandible relative to the cranium. Teeth, therefore constitute the factor that most influences occlusion. A shift in the mandible influences the masticatory muscles and the jaw joint that form the functional occlusion system. These two components can either accommodate this change or manifest with symptoms of pain and discomfort (Fig. 3-3-4). It is generally known that individuals with strong resistance are unlikely to experience masticatory muscle pain or develop temporomandibular dysfunction syndrome. This concept is similar to that encountered with cases where poor oral hygiene does not necessarily lead to periodontal disease. In some patients, it cannot be ruled out that general malaise might arise as a result of a slight difference in the height of the bridge. Another example is where two molars that were removed to treat periodontal disease were not replaced. The neighboring teeth started to incline towards the empty space resulting in premature contact. As the patient started to avoid contact with these affected teeth, the mandible was gradually displaced from its original position.

In general practice, even with this poor understanding of occlusion and its effects, it is suggested that there are still few cases that present with malfunction of the masticatory muscles or temporomandibular joint because of the presence of protective factors in some individuals. Even with the prevalence of strongly adverse factors, the resistance of the functional occlusion system and factors that preserve it prevail. When the adverse factor and protective factor are balanced, this is termed individual, normal occlusion; when the adverse factor is stronger than the protective factor, this is apparent malocclusion; and when the protective factor predominates over the adverse factor, this is called inapparent malocclusion. (Fig. 3-3-5).

Changes to the Teeth(Contact)

- Tooth attrition
- Abrasion
- Bruxism
- Slope of adjacent tooth loss
- Extrusion of opposing tooth loss
- High restoration
- Lack of occlusal adjustment for dentures
- Mistake of bite taking
- External wound
- Orthodontic therapy
- Emotional stress etc

Fig. 3-3-3

Various changes to teeth can shift the mandibular position “muscular position”

Teeth constitute the factor that most influences occlusion

(Attack factor)

Masticatory muscle

(Accmodator)

Jaw joint

(Accomodator)

Fig. 3-3-4

Changes to teeth affect the masticatory muscle and jaw joint, resulting in the shifts in the mandibular position.

Balance

Attack factor

(Change of teeth and muscles)

>

=

<

Protection factor

(Resistance of functional occlusion system)

Normal occlusion

(Individual normal occlusion)

Apparent malocclusion

Inapparent malocclusion

Fig. 3-3-5 By the shifts in the balance of the protective and adverse factors give rise to a variety of adjustments in the mandibular positions: individual occlusion, apparent malocclusion, and inapparent malocclusion.

[A shift in the mandibular position relative to the cranium overloads the implanted prosthesis]

Fig. 3-3-6 illustrates an example of tapping where contact sliding is performed in centric occlusion (CO) caused by dislocation of the mandible after occlusal contact in the MCP. The chewing pattern which results in cases such as this, a gliding motion known as “hit and slide”¹⁰, can be observed as the mandible slides from the MCP to centric occlusion, as shown in Fig. 3-3-6. If this pattern is observed at the time of consultation, this is an indication that there is a possibility that the implant prosthesis will repeatedly experience lateral stress and rotational force. By modifying the occlusal interactions or the width of the occlusal plane, it should be possible to control the lateral force or the rotational forces to some extent, however, there is a general consensus that they should be treated to restore the MCP so that functional occlusion is not affected.

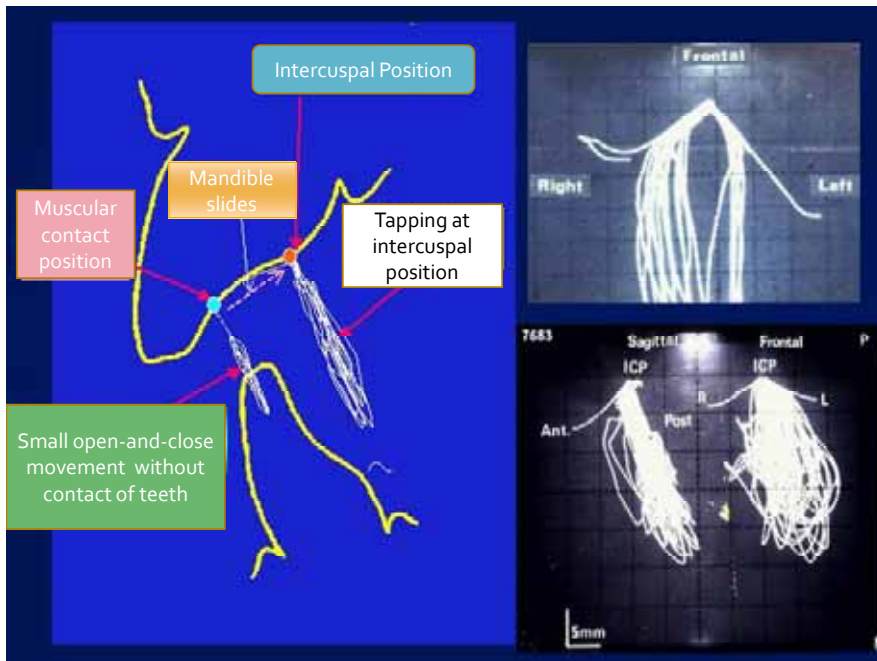


Fig. 3-3-6

Upon dislocation of the mandible relative to the position of the skull, the chewing patten that often follows this is where the mandible slides in a gliding motion from the MCP to centric occlusion after occluding to the muscular position. This may not appear to be a major problem, but this motion acts as a lateral, and rotational occlusal force on the implant body

E. A case study in which physiological occlusion therapy improved the occlusion, with placement of an implant prosthesis

This chapter discusses the examination, treatment methods, and results, supported by a case study of a patient (referred to as Y.T), in order to further the understandings of functional occlusion that will be useful in placement of implant prosthetics.

This 34 year-old female patient (a housewife) arrived with concerns as which part of the mouth she can chew with, and requested overall treatment of her jaw including implant prosthetic surgery (Fig. 3-3-7). From the dental and panoramic radiograph, the No. 27 is shown to have P3 and a apical lesion in the maxilla frontal teeth (Fig. 3-3-8). Currently, she also has tension in the back of her neck, stiff shoulders, body strain and dry eyes.

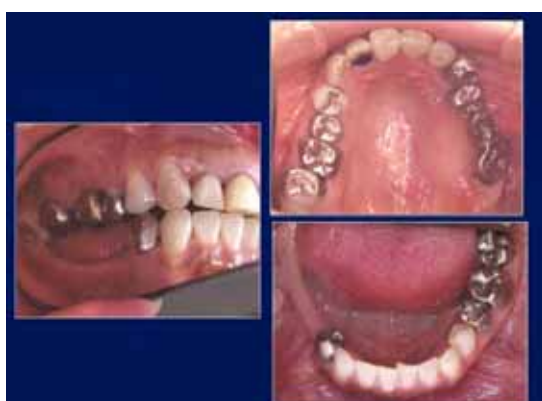

Fig. 3-3-7

The images of the intra-oral cavity of Y. T. at the time of first medical examination

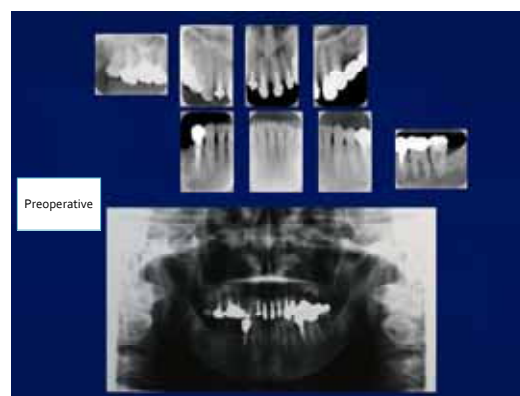


Fig. 3-3-8

Dental radiograph and panoramic radiograph of Y.T. at the first medical examination

[Examination of occlusion (Rapid movement of opening and closing of the mouth)]

The examination of the occlusion, in conducting implant prosthetic treatment, should be done with the aim to avoid any excessive occlusal force to act on the implant prosthesis, with objective evaluation of the functional occlusion. Each elements of the functional occlusion system were examined using computerized mandibular scanning (CMS) K7 Evaluation system¹¹⁾ that had been incorporated with the dental electromyography and joint sonography that was a further developed from the MKG that were used previously.

The recording of the case Y.T. undergoing rapid opening and closing of the mouth movement is shown in Fig. 3-3-9, with the velocity curve shown (left) that is the differential of the vertical component taken from the opening and closing of the mouth movement. The state in which the masticatory muscle group acts in sync with each other during opening and closing the mouth, a smooth lissajous curve is drawn. The recordings of the present case thus show no problems with the masticatory muscles. However, the tracking of the pathway in the coronal plane show no consistency and do not conform to one mandibular position, which is reflected in patient's complaint of not knowing in which position to chew.

The kinesiograph recorded while tapping twice at the centric occlusion from the mandible rest position is shown in Fig. 3-3-10. The three graphs show the up-down movement (top), the front-back movement (middle) and left-right movement (bottom).

In a standard functional occlusion system, the free-way space from the muscular contact position is roughly 1.0 mm (± 0.5 mm) and the ratio of vertical and longitudinal motion do not deviate from 1:1 to 3:1. In this patient however, when shifting from the mandible rest position to the occlusal position, the longitudinal movement was found to be more significant than the vertical movement, with a relatively small free-way space that was particularly unstable at the centric position. With regard to the horizontal movement, there is cuspal interference to the left of the muscular contact position, and the tapping was performed by avoiding this, in an unstable state.

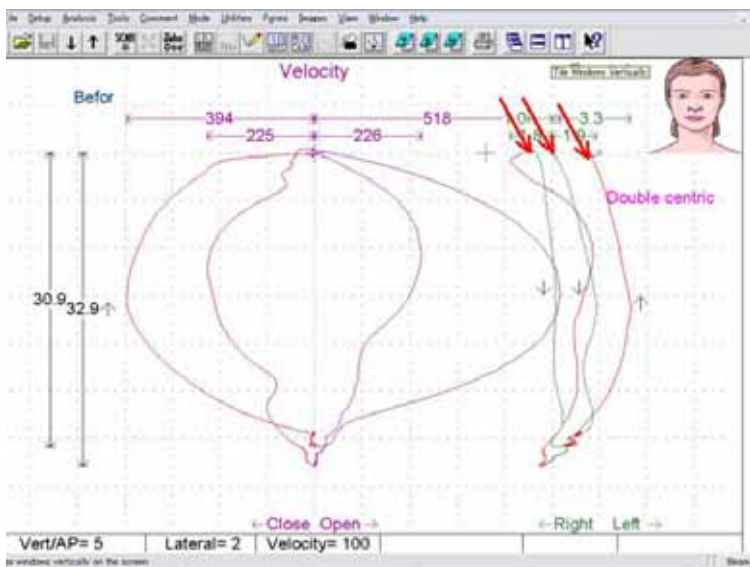


Fig. 3-3-9

The preoperative occlusion examination of Y.T. (rapid switching aperture movement) mandibular position changes every time she chews, and is therefore unstable

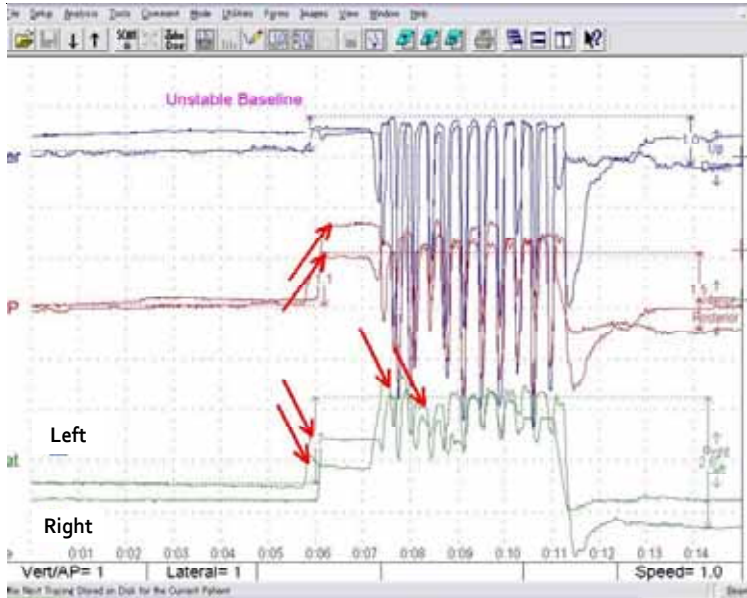


Fig. 3-3-10

The preoperative occlusion examination of Y.T. (tapping and rest position) mandibular position is extremely unstable as shown in three dimensions

[Examination of the jaw joint]

The examination of the temporomandibular joint is essential component of functional occlusion system. At the medical examination conducted ten years ago, an arthrosound was presented. However as there were no pain symptoms, it was left untreated. From this, the disc displacement was suspected. From palpation, a clicking was heard in the right temporomandibular joint during the mouth opening and closing therefore a MRI scan was conducted for further examination.

The MRI recording of the present case is shown in Fig. 3-3-11. A non-restorative articular disc anterior dislocation is featured on the left, and restorative articular disc anterior dislocation on the right. Taking into consideration, the absence of subjective symptoms, the age, and the degree of deformation, it was decided that the correction of the articular joint was not practical, and with consent from the patient, the mandibular position (muscular contact position) that was best for the functional occlusion in this state was attempted to be achieved.

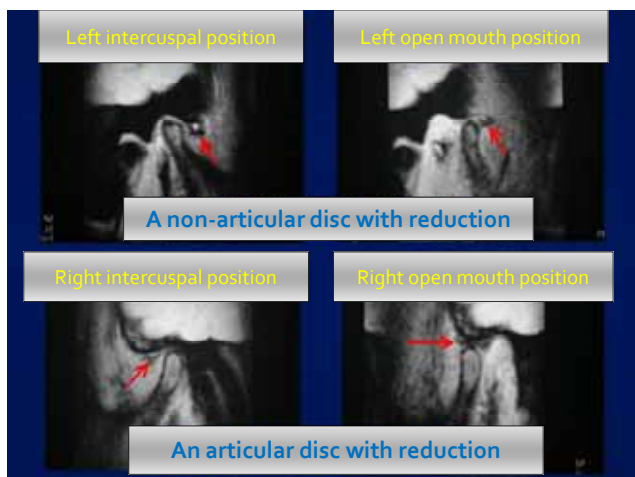


Fig.3-3-11-

MRI record of Y.T. Left temporomandibular joint disk is a non-articular disc with reduction and right disc is an articular disc with reduction

[Examination and treatment plan]

The findings indicated that the masticatory dysfunction in this case to have resulted from the shift in the mandibular position relative to the skull. The treatment for this was decided to be conducted in the

following order, after undergoing the diagnostics:

- a) Examination of occlusion with K7 Diagnostic system
- b) MRI examination of the jaw joint
- c) Extraction of No. 2 tooth
- d) Intradental treatment of the maxillary frontal, No. 5 and No. 21 teeth
- e) Construction of removable orthosis at the muscular contact position
- f) Re-fabrication of crowns to the teeth No. 4, 5, 6, 7, 8, 9, 10, 11, 12, 13, 14, 15, 21, 30 and 31.
- g) Placement of unilateral distal extension bar removable partial denture (RPD) with attachment
- h) Perioperative examination of the occlusion with K7 Diagnostic system (for confirmation of the correction of occlusal position and re-evaluation of functional occlusion).
- i) Implant treatment for No. 19 and 20.
- j) The postoperative examination of the occlusion with K7 Diagnostic system.

The removable orthosis (Fig. 3-3-12) was fabricated by impression taking at the muscular contact position after the intradental treatment. Orthosis is a device that is employed to correct the displacement of the mandibular position in relation to the skull. The different types consist of: provisional restoration¹²⁾, removable orthosis to replace the missing teeth, Auto-repositioning appliances (Shore)¹³⁾.

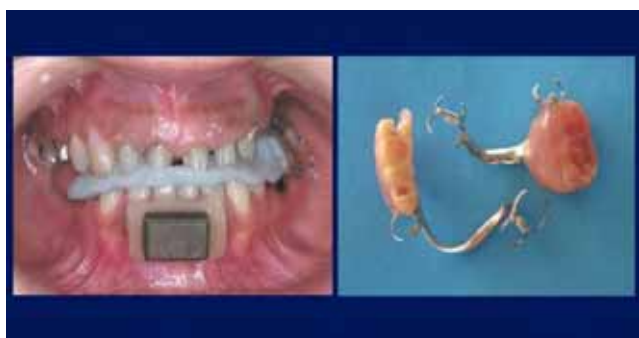

Fig. 3-3-12
Occlusal impression taking at the muscular position and removable mouthpiece

[Perioperative examination]

The position of the mandible was analyzed to determine whether its position had been corrected in relation to the skull with the application of the removable orthosis.

The recording of a number of opening and closing movements of the mouth with the placement of removable orthosis that was fabricated at the muscular contact position, to adjust it to occlude at the muscular contact position is shown in Fig. 3-3-13. Here, the curve shows that the mandibular position to have been corrected, and the jaw movement to have been restored close to the norm.

The coordination of the masticatory muscles during the rapid mouth opening and closing showed no significant differences between before and after the surgery. By adjusting the displaced mandibular position to the muscular contact position, the occlusal position became stabilized at the muscular contact position and narrowing the opening and closing of the mouth.

The recordings after the placement of the crown bridge, key & way attachment unilateral extension bar RPD is shown in Fig. 3-3-15. The prosthetics were placed at the muscular contact position since the application of orthosis had restored the displacement of the mandibular position in relation to the skull. The ratio of vertical movement as well as the anteroposterior movement were improved close to the norm, but due to the fact that there has not been much time since the attachment of the crown or RPD,

instability can be seen in the anterioposterior direction with a slight displacement to the left side.

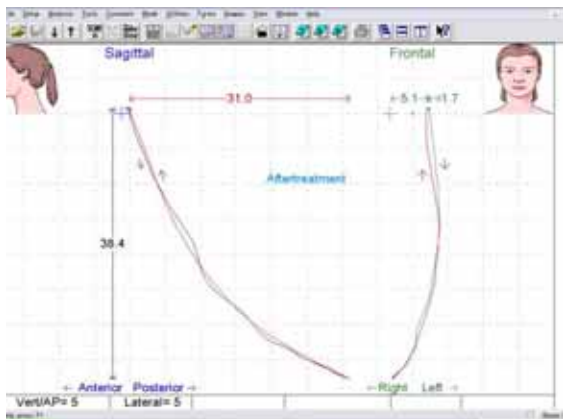


Fig. 3-3-13

Intraoperative occlusal examination – the rapid switching aperture movement at the muscular position with the placement of removable mouth piece has returned to the norm

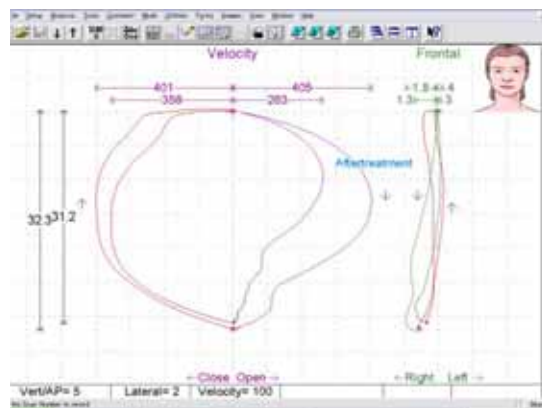


Fig. 3-3-14

Intraoperative occlusal examination – the rapid switching aperture movement always returned to the muscular position and returned to the norm

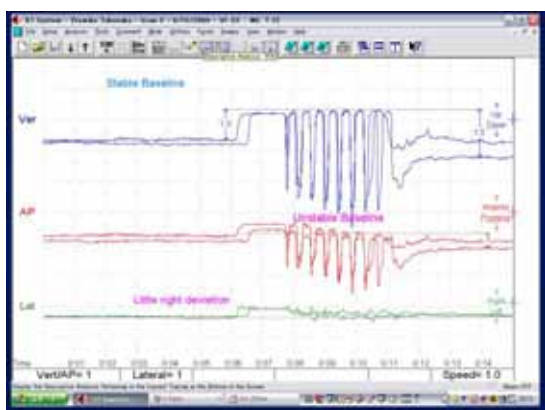


Fig. 3-3-15

Intraoperative occlusal examination – instability in the longitudinal direction, with a shift of 0.3mm from muscular position but the condition has been improved overall

[Perioperative examination of the jaw joint]

TMJ radiogram taken by a standardized technique, the individualized anatomic X-ray aligner “condyray”, after the occlusal correction with orthosis is shown in Fig. 3-3-16.

Although the left articular disc is shown to have been dislocated, the mandibular condyles on both sides are positioned at the centre of the temporomandibular fossa in the occlusal position as well as in the rest position. The articular joint spaces are also evenly distributed longitudinally.

The left two images of Fig. 3-3-17 features the electrical discharge of the anterior bellies of the temporal muscles and the masseter muscles on the left and right, recorded at the time of strong masticatory force application with the natural teeth without any mediators. The images on the right shows the recording with the application of strong masticatory force in the presence of roll of cotton placed in between the teeth. The amount of electrical discharge and the ratio both indicate its recovery to the norm. The results confirmed the mandibular position to have been corrected to the position of the muscles, and that the masseter muscle group to be functioning in a coordinated manner.

From these findings it was concluded that the mandibular position in relation to the skull had been

corrected, and that unwarranted occlusal pressure would not be exerted onto the implant body installed, therefore implant prosthetic treatment was performed (Fig. 3-3-18).

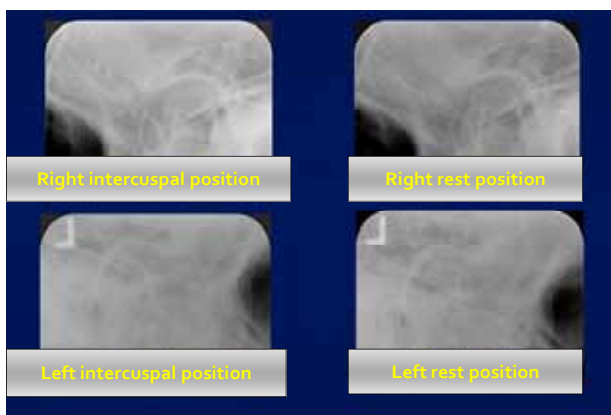

Fig. 3-3-16

Intraoperative occlusal examination – the left disc is non-articular but the extent of the gap is the same in both sides, front and back, and the mandibular condyle is placed in the middle of glenoid cavity.

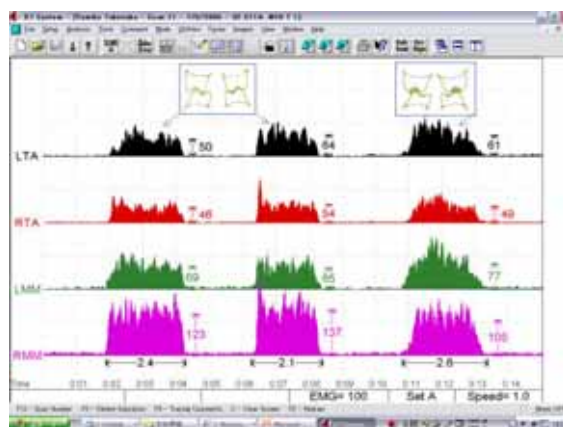


Fig. 3-3-17

Occlusal examination after placement of the removable mouthpiece (the magnitude of muscle discharge when clenched) – The dislocated mandibular position was corrected. Both the natural teeth (two on the left), mediated with cotton roll (one on the right) were corrected in the magnitude of muscle discharge, and the ratio of temporal muscle anterior belly discharge and masseter muscle discharge.

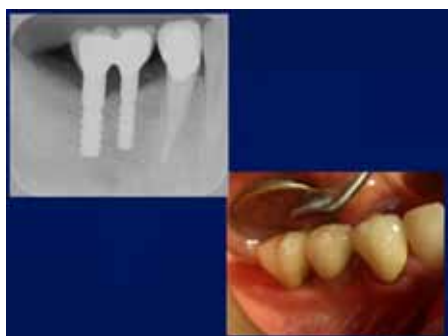

Fig. 3-3-18

Implant prosthetic surgery was performed once the shift in the mandibular position with respect to the cranium was restored to the muscular position.

F. The effect that an implant prosthesis has on occlusion

This part will describe the care required after treatment of malocclusion to restore function in a manner that will last safely and stably, for a long duration.

[The fundamental differences between implants and natural teeth]

The differences between natural teeth and implants is that implants have no sensory receptors and interference mechanism. Therefore, the feedback information from the periodontal sensory receptors present in the natural teeth is lost. The reason why people who have a full denture on both the upper and lower jaws are still able to chew, articulate and swallow, is mainly due to the sensory receptors present in the masticatory muscles and the temporomandibular joint (Fig. 3-3-19). The graphs shown in Fig. 3-3-20 illustrate a significant difference in the mobility of the implant with applied occlusal force, compared to

that in the natural teeth. The natural tooth is greatly affected initially by a small load, followed by more gradual change. The periodontal membrane undergoes viscoelastic deformation, so slight loading can result in an abrupt change, and then, with an additional load, a more gradual change. Therefore, up to loads of 1000g, the main modification will be to the periodontal membrane, with no effect on the alveolar bone.

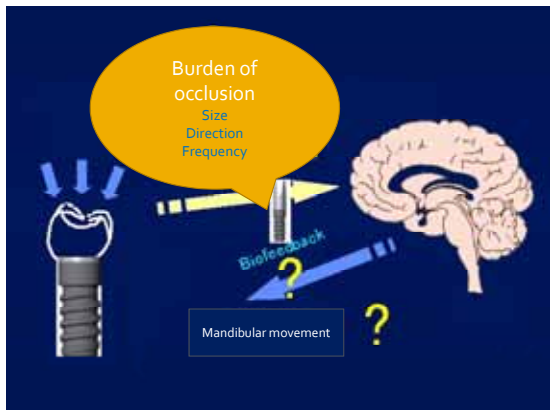


Fig. 3-3-19
The implant that lacks ligaments in the surrounding structures and the functional occlusion

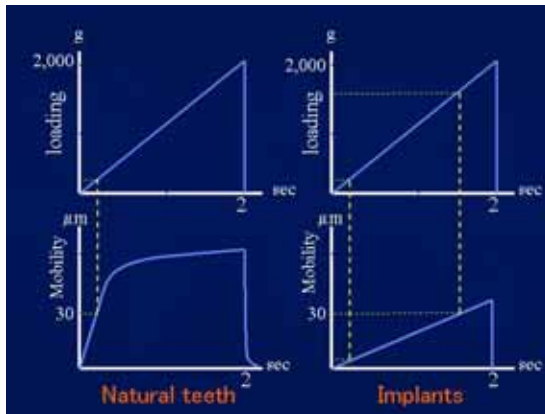


Fig. 3-3-20
The difference in transmission of the occlusal forces between natural teeth and implant

In contrast, with an implant the load will directly affect the alveolar bone from the beginning. This implies that possibility that the alveolar bone surrounding the implant will be affected by external forces^{14), 15)}. In locations where both natural teeth and implants exist, it is usually the implant that experiences masticatory forces. Therefore, theoretically, the implant prosthesis should be fixed so that it receives the same amount of occlusal force as the natural teeth with slight chewing, in a manner referred to as, “implant protected occlusion”, where the occlusal contact of the implant prosthetics is slightly less than that experienced by the adjacent natural tooth (Fig. 3-3-21).

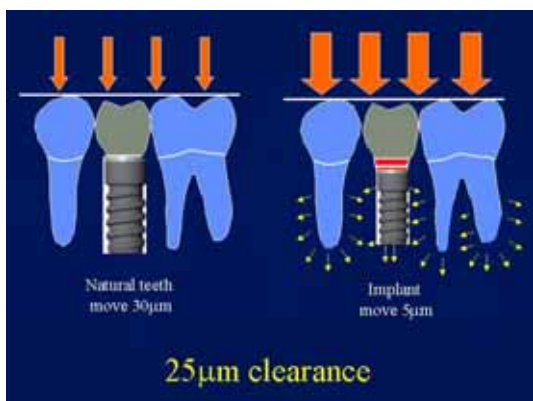


Fig. 3-3-21
The difference in degree of sinkage between natural teeth and implant

G. Dental overload and implant prostheses

There must be numerous people with two-piece type implants who have experienced loosening of the screw or damage to the frame after a few years. Vertical force on the screw axis of the superstructure, or

lateral forces, which act directly on the structure, have been considered the responsible factors. The solutions to these failures are as follows: avoid placing the occlusal contact at a point where it is distant from the central axis of the implant, and where the area of contact is large; in particular, take great care when the point of contact is located in a site that works as a cantilever; improve the accuracy with which the framework is fitted; treat bruxism; change to a one-piece type.

In my clinical experience, when using the two-piece type, there were a number of cases where loosening of the screws in the implant connection occurred after several years. Once the HA-coated one-piece type was adopted, there have not been any problems, resulting in a safe and secure treatment option that is pleasant and advantageous for the patient.

[The effects of excessive load on osseointegration of the implant]

Is excessive load, one of the causative factors for resorption of the bone, present around the implant? The answer to this question cannot be obtained easily, as those clinical studies that have looked into the causative mechanisms contain contrasting observations ¹⁶⁾. Some studies have addressed the biological complications, such as infection as a factor in addition to excess load. For example, in one report ¹⁷⁾, bone resorption arose as a result of excess loading, and then progressed due to contamination with bacteria from periodontal disease present in the depth of the pocket. In animal studies that used monkeys or dogs, on placing a taller superstructure, it was found that loss of osseointegration occurred, even though initial osseointegration was established ¹⁹⁾. In contrast, in another study where a superstructure with an excess height of 3 mm was placed in human subjects, the amount of bone resorption did not differ significantly from that seen in controls ²⁰⁾.

It can at least be said that implant prostheses installed in patients with bruxism are likely to undergo bone resorption, and the bones surrounding the implant may be damaged in the initial stages. The use of night guards is essential in these patients. This fact has become a consensus opinion for management of those with extremely severe bruxism, but even in those who have very mild or no bruxism, the possibility of occurrence of marginal bone resorption cannot be ignored in the long run.

From a general point of view, it cannot be said that normal loads exerted on the implant from normal occlusion are without effect on the bones in the margin of the implant. To secure long-term stability, it is important to decrease the risks of excessive loading as much as possible.

[Anti-axial loading and bone resorption]

During preparation of the implant prosthesis, even if the appliance is designed and moulded on the model, and the location and direction of implantation are determined with the use of stents, this does not automatically result in implantation in an ideal position and in the direction that was initially planned. Anti-axial loads can exert a large bending moment on the implant, and this results in bone absorption as has been proven in an experiment using dogs ²¹⁾. What is an acceptable amount of tilt? There have been no studies of single implants installed at angles between 15° and 45°, but there has been a report that bone resorption does not result if the superstructure is connected. It is best to implant single implants without any tilt, and for the occlusal force to act on the long axis of the implant, as much as possible. Where implantation was done at an angle, it is thought that the only solution to control the overload is to modify the occlusal contact.

[The width of occlusal contact] (Fig. 3-3-22)

Off-axis excess loading can occur as a result of designing a occlusal surface that is larger than the diameter of the implant axis, so that all pressure is exerted on this occlusal contact. Twil et al. investigated resorption of the marginal bones by dividing occlusal contact areas into four different widths that varied from less than 6 mm to more than 8 mm. They reported that there was no significant correlation between the width and the extent of bone resorption observed. It has to be noted that this study used two implants that were connected to each other, instead of a single implant. I believe that even when a molar is being replaced, the width of the occlusal plane should be the same as that of the premolar, as in the diagram. There are instances where the width of the occlusal plane of the premolar prosthesis is not much different from that of the natural teeth. However, even in cases where the implants are connected to each other, the width of occlusal contact should be limited, and the focus of the force should be applied as close to the axis as possible. If an esthetic problem arises as a result of this, then it will become important to control excessive load by altering the location of the occlusal contact.

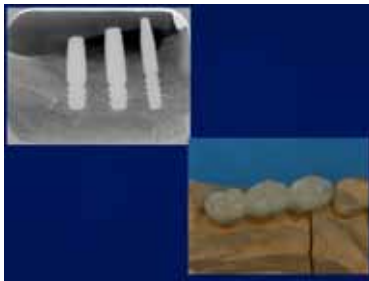

Fig. 3-3-22

The width of occlusal plane of implant prosthesis

[Connection with natural teeth] (Fig. 3-3-23)

As shown in Fig. 3-3-23, there is a difference in the extent to which the tooth sinks when a load is applied in an axial direction to the natural tooth which has a dental annular ligament, and implants. With replacement of the last maxillary molar, the question arises as to whether it is appropriate to bridge the crown with the natural adjacent tooth using either rigid fixation or semi-fixation. The intention here is of course to strengthen the crown and implant prosthesis, but various authors are divided in their views. On one hand, both rigid fixation and semi-fixation are considered acceptable ²⁴⁾, but others suggest that in creating a connection, both the adjacent teeth and the implant will result in subsidence ²⁵⁾. The results of meta-analysis indicated that in the long run, the link will lead to a decreased implant survival rate ²⁶⁾. In my experience too, loosening of the screw in a semi-fixed implant has resulted after ten years. It can be said that short-term use of stabilization with the natural adjacent teeth does not cause much of a problem, however, long-term use decreases the implant survival rate and therefore, to be on the safe side, its use should be avoided.

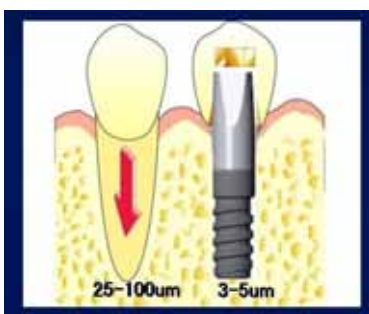

Fig. 3-3-23

The difference in degree of sinkage between natural teeth and implant

[Occlusion of the single-tooth implant prosthesis]

Install the implant prosthesis so that only light contact occurs with centric occlusion with forceful mastication, and direct the occlusal force along the long axis of the implant as much as possible. Also avoid eccentric occlusion in so far as possible. If the implant is installed at an angle, set the prosthesis so that the only contact is at position A, as illustrated in Fig. 3-3-24.

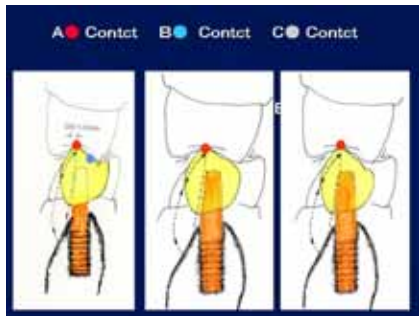


Fig. 3-3-24

The point of contact that controls the excessive loading. The distances of less than 13 mm, excess loading can become a problem if the contacts are formed on points A, B and C. Contacts formed on points A and B, or only on A is favorable

[Difficulties with implant prostheses placed posteriorly, and their occlusion] (Fig. 3-3-24)

As is well known, the loss of natural dentition occurs in the following order: maxillary second molar, maxillary first molar, mandibular molars. Many people have likely experienced breakage of porcelain superstructures with exposure of the frame, within a few years. The reason for this is that masticatory movement occurs geometrically, with the jaw joint as the 'axle'. Visualization of the operation of a pair of scissors might be the easiest example to illustrate this concept. The quadrature portion of the masseter muscle, which is the generator of occlusion, is located in a position that resembles the pivot of the scissors, and therefore the teeth close to this pivot experience a greater, continuous occlusal force than the frontal teeth. The posterior teeth are also difficult to brush due to their location, therefore, the periodontal tissues are generally much weaker than those surrounding the other teeth. In addition, if the patient has a habit of chewing with greater masticatory force than normal, and added effects are present, such as a distal shift of the mandibular position, tooth loss can result from strain due to overload.

Implementing consistent tooth brushing or fixing the mandibular position in relation to the skull can be done in order to improve the situation, however, the strength of the masticatory force and the location of the masseter muscle in centric occlusion is fixed and cannot be modified. Possible solutions are thus to examine the extent of tooth abrasion and attrition, bulging of bone, and occlusion before the operation; to reserve clearance of over 2 mm between the prosthesis and the opposing teeth; to fit crowns made of alloy metals, rather than porcelain, with appropriate explanation, and unless the patient is in show business; and not to deceive the patient by telling him/her that the popular hybrid resin is a ceramic crown. Even a frontal replacement can be subject to early attrition, exposing the metallic part, and this can result in shift of the mandible.

The occlusion should be set so that the molars are in disclusion during any mandibular movement. If disclusion cannot be established, resolve this with the use of cuspid rise ²⁷⁾. The plane of occlusion should be minimized as much as possible, and the occlusal plane at the maxillary second molar should be reduced from a quarter to a half.

[Occlusion of the prosthesis of full denture implants]

Forms of “mutually protected occlusion” or “lingualized occlusion” should be used where full denture prosthesis is created, in order to protect the frontal teeth from experiencing excessive contact.

[Occlusion of an overdenture]

When supporting a maxillary overdenture with four implants, this requires the support of the palate, similarly to normal artificial dentures. In the case of poor bone quality, or where bone has been augmented, six implants are required for support.

For a mandibular overdenture, either support it by connecting two ball anchors (zest attachment, locator attachment) or with a bar. Fully balanced occlusion should be provided where the extent of bone resorption of the alveolar ridge is slight, and where there are no problems in the relationship with the occlusive teeth. However, a progressive increase in the bone resorption of the alveolar ridge is more common where the relationship with the occlusive teeth is problematic. Lingualized occlusion, as shown in the diagram, should be provided (Fig. 3-3-25).

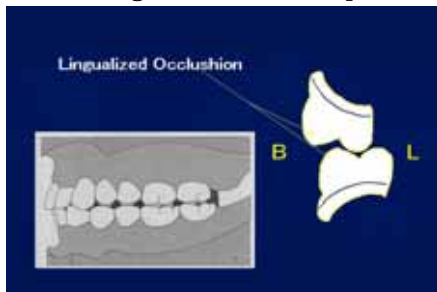


Fig. 3-3-25

The occlusion applied on the overdenture that supports the implant

[Bruxism and implant prostheses]

There is consensus that the phenomenon of bruxism occurs as a result of people releasing their frustration. No effective treatment has been developed, and bruxism is a contraindication for implant treatment. Recently, a simplified measuring device, called the Bite Strip (S.I.P. Ltd) was developed and has been marketed as a way of determining whether a person is a bruxer and the extent to which this occurs. If it is determined with a Bite Strip that the person has bruxism, avoid an implant or if the patient persists in demanding one, he/she should agree to wear a protector. The patient may not comply, and in these circumstances it may be impossible to determine the reason for a problem, and where the responsibility lies. For this reason, if it has been determined on testing that the patient is a strong bruxer, the condition should be regarded as a contra-indication for implant treatment.

[The pros and cons of immediate loading]

As previously mentioned, at the start of this century the main aim of implant treatment clearly shifted to improvements in patient QOL, which in turn has made shortening of the treatment period the subject of further development. One way to reduce the period of treatment is to adopt immediate loading, with application of occlusion immediately following installation. The major advantage of this method is that healing can be stimulated by applying pressure. A tooth that is attractive to the patient can also be formed in the space of one day.

The one disadvantage of this method is that osseointegration has not yet been established, therefore, an unstable period can persist for several weeks after the onset of loading. In the research conducted by Oh

and Ericsson *et al.* 28). 29), roughly 20% of such implants failed. If an aesthetic implant is a requirement for replacement therapy, the implanted body should be completely devoid of any occlusal pressure, and not be functional. Regarding implants of anterior teeth, the bones on the buccal side tend to be thin, therefore, the structural change from before to after surgery is much more distinct than with the molars. It is generally believed that two months is adequate for molar replacements to stabilize, but with the frontal teeth, a period of at least three months is required. A longer period is required if bone augmentation with guided bone regeneration (GBR) has been applied. Consequently, it can be said that final restorations should not be put in place initially, before changes to the interdental papilla can be predicted. In addition, in the absence of any support for the soft tissues, it has been said that loss of the interdental papilla can be accelerated. It can therefore be concluded that there is a significant number of problems related to the immediate loading method of implant insertion, with regards to the effect it has on occlusal contact.

III. Postscript

The best occlusion that can be accomplished with an implant prosthesis can be said to be one that has been controlled biomechanically, and within the tolerance limits of the prosthetics, so as to establish long-term stability of the implant body and the superstructure. In other words, long-term stability of the implant prosthesis is dependent on the ability to exclude those factors that augment occlusal overloading.

References

- 1) Hinohara S. POS the problem oriented system New system for reform of medical care and medical education. Tokyo. 1973. (in Japanese)
- 2) Yamashita A. Seeking for clinics, studies, and education that open dentistry in the 21st century. Tokyo. Ishiyaku Pub,Inc. (in Japanese)
- 3) Yamashita A. Basic and clinical study of dental adhesive resin (Last volume). Tokyo. Quintessence Publishing Co., Ltd. (in Japanese)
- 4) Yatani H. 8020 and prosthetic treatments : A review of the literature. Journal of the Japan Prosthodontic Society. 2005; 49:190-198. (in Japanese)
- 5) Yatani H. Prosthodontic failure and its risk factors: A review of the literature. Journal of the Japan Prosthodontic Society. 2007; 51: 206-221. (in Japanese)
- 6) Kawamura Y. Oral physiology. Kyoto. Nagasueshoten Co., Ltd. 1972; 249.(in Japanese)
- 7) Jankelson B. and Swain C W .Physiological aspects of the masticatory muscle stimulation:the Myo-monitor. Quintessence Int 1972; 3: 57-62.
- 8) Brill N and Tryde G Physiology of Mandibular Position. Font Oral Pysiol.1974; 1: 199-237.
- 9) Brill N and Lammie G A Osborne J, and Perry H T. Mandibular position and mandibular movement, A review. Brit Dent J. 1959; 106: 391-400.
- 10) Yamashita A, Yatani H, Kuboki T. Advanced physiological occlusion and treatment of temporomandibular joint disorder.Tokyo. Quintessence Publishing Co., Ltd. 1993: 52. (in Japanese)
- 11) K7 Evaluation System users guide. Seattle, WA. Myotronics-Noromed, Inc, 2002.
- 12) Shore N A. Tempolromandibular joint dysfunction and occlusal equilibration, 1976; 2nd ed: 273-249.
- 13) Ikeda M, Takamatsu H. Basic and clinical study of nueromascular concept, Volume 1-Seeking for

fusion of aesthetics and functions-. Kyusyu Kinesio Club Textbook.2006: 180 - 184. (in Japanese)

- 14) Skalak R. Biomechanical considerations in osseointegrated prostheses. *J Prosthet Dent* .1983; 49(6): 843-852.
- 15) Parfitt G S. Measurement of the physiologic mobility of individual teeth in an axial direction. *J Dent Res*.1960; 39-68.
- 16) Adell R, Lekholm U, Rockler B, Brånemark P I. 15-year study of osseointegrated implants in the treatment of edentulous jaw.*Int J Oral Surg* 10.1982; 387-416.
- 17) Lang N P ,Wilson T G, Corbet E F. Biological complications with dental implants:their prevention,diagnosis and treatment.*Clin Oral Implants Res* 11 (Supplemental). 2000; 146-155.
- 18) Quirynen M, Naert I, Steenberghe D. Fixture design and overload influence marginal bone loss and implant success in the Branemark system. *Clin Oral Implants Res* 3.1992; 104 -111.
- 19) Isidor F. Loss of Osseointegration caused by occlusal load of oral implants. *Clin Oral Implants Res*7.1996; 143-152.
- 20) Heitz-Mayfield LJ,Schmid B,Weigel C et al.Does excessive occlusal lord affect Osseointegration? An experimental study in the dog. *Clin Oral Implants Res*15.2004; 259-268.
- 21) Barbier L, Schepers E. Adaptive bone remodeling around oral implants under axial and nonaxial loading conditions in the dog mandible. *Int J Oral Maxillofac Implant*. 1997; 12: 215-223.
- 22) Sethi A, Kaus T, Sochor P. The Use of angulated abutments in implant dentistry: five-year clinical results an ongoing prospective study. *Int J Oral Maxillofacial Implants*; 2000; 15: 801-810.
- 23) Tawil G. Aboujaoude N, Younan R. Influence of prosthetic parameters on the survival and complication rates of short implants. *Int J Oral Maxillofac Implant*. 2006; 21: 275-282.
- 24) Hosny M M F, Duyck J, Steenberghe D V, Naert I. Within subject comparison between connected and nonconnected tooth-to-implant fixed partial prostheses:up to 14year follow-up study.*Int J Prothodont*. 2000; 13: 340-346.
- 25) Naert I E, Duyck J A J, Hosny M M F, Quirynen M, Van Steenberghe D. Freestanding and tooth-implant connected prostheses in the treatment of partially edentulous patients.Part 1: An up to 15-years clinical evaluation. *Clin Oral Implants Res*.2001: 12: 237-244.
- 26) Pjetursson B E, Tan K, Lang N P Tan K, Pjetursson B E, Lang N P, Chan E S Y.
A systematic review of the survival and complication rates of fixed partial dentures (FPDs)after an observation period of at least 5 years I.Implant-supported FPDS. *Clin Oral Implants Res*.2004; 15: 625-642.
- 27) Yamashita A, Kuboki T, Kondou Y, Imai M, Minakuchi H. Cuspid rise by adhesive technique for protection of adjacent teeth to canine teeth. The 32nd annual scientific meeting of Japan Prosthodontic Society Chugoku & Shikoku Branch. 2006.
- 28) Oh T J, Shotwell J L, Billy E J, Wang H L. Effect of flapless implant surgery on soft tissue profile: a randomized controlled clinical trial. *J Periodontol* 2006; 77: 874-882.
- 29) Ericsson I, Nilson H, Lindh T, Nilner K, Randow K. Immediate functional loading of Branemark single tooth implants. An 18 months clinical pilot follow-up study. *Clin Oral Impl Res* .2000; 11: 26-33.